

Perianal giant condyloma acuminata in an infant: an alarming lesion for a pediatric surgeon

Elif Altınay-Kırlı¹, Şafak Güçer², İbrahim Karnak¹

Departments of ¹Pediatric Surgery and ²Pediatrics, Hacettepe University Faculty of Medicine, Ankara, Turkey

SUMMARY: Altınay-Kırlı E, Güçer Ş, Karnak İ. Perianal giant condyloma acuminata in an infant: an alarming lesion for a pediatric surgeon. Turk J Pediatr 2011; 53: 333-336

Condyloma acuminatum (CA), which is a large cauliflower-like tumor, has been linked to human papilloma virus (HPV) types associated with skin warts. It is an uncommon condition in children, and there is no consensus regarding the optimal treatment. HPV may be acquired via sexual transmission, vertical transmission or extragenital contact. We report herein a 1.5-year-old girl with perianal giant CA, which developed due to extragenital contact and consisted of HPV types 6 and 18, to emphasize the effectiveness of surgical excision.

Key words: anogenital wart, condyloma acuminata, human papilloma virus, perianal wart, surgery.

Condyloma acuminatum (CA) is a large cauliflower-like tumor, originally described by Buschke and Löwenstein^{1,2}. It has been linked to human papilloma virus (HPV) types associated with skin warts. Most patients are in the adult age group. Although the exact incidence of CA is not known, it is rarely encountered in children.

Human papilloma virus (HPV) may be acquired via sexual transmission, vertical transmission or extragenital contact. The mode of transmission may not be clearly elucidated in each case. Since 50% of anogenital warts in children older than five years are secondary to sexual abuse, a particular attention has to be given to the possibility of sexual abuse.

There is no consensus on the treatment of perianal warts in the childhood period. Treatment options include topical applications of creams, cryotherapy, laser vaporization, electrocautery, and surgical excision²⁻⁴. These treatment modalities, except surgical excision, can be painful for a child, expensive, and time-consuming, and recurrences are common.

An infant with giant CA is presented to emphasize the effectiveness of surgical treatment in infants with giant perianal warts.

Case Report

A 1.5-year-old girl was admitted to our unit with an enlarging perianal mass of one-year duration. Topical therapies including cream and cryotherapy had been tried but failed because of the parents' noncompliance with the treatment. Her medical history was unremarkable for long-standing or recurrent illnesses or immunological disease. The parents were separated at the time of admission.

Physical examination revealed multiple, pedunculated and cauliflower-like lesions around the anus (Fig. 1). The patient underwent detailed examination and biopsy under general anesthesia. Rectal touchè was normal. There was no sign of sexual abuse in the perianal or vulvar regions. Introitus was normal with intact hymen.

Histopathological examination demonstrated acanthosis and parakeratosis in the epidermis. Koilocytes and rare dyskeratotic cells were seen in the stratum spinosum layer. Elongation and thickening were seen in the rete-ridge (Fig. 2). Basal membrane was intact, and dilated vessels and infiltration of mononuclear inflammatory cells were seen. Polymerase chain reaction (PCR) and *in situ* hybridization studies showed that the tumor cells were positive for HPV type 6 and type 18. The histopathological diagnosis was CA.

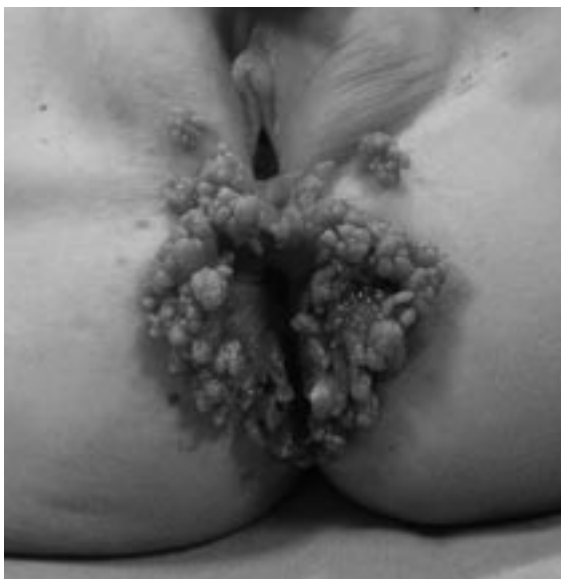

Fig. 1. Perianal condyloma acuminatum with multiple, pedunculated and cauliflower-like papillary lesions.

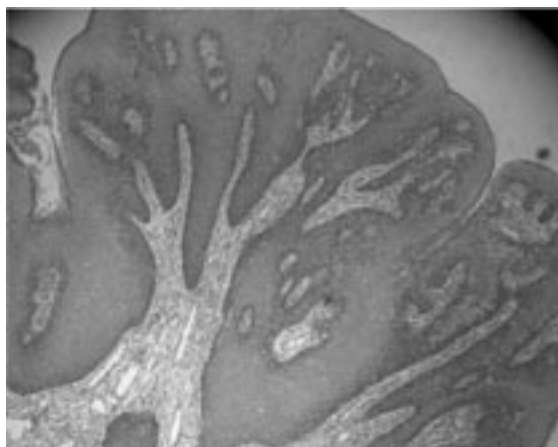


Fig. 2. Acanthosis and parakeratosis with elongation of rete ridges are noted. There is also mild mononuclear inflammatory cell infiltration in the upper dermis.

Detailed family history was obtained three weeks after admission, and it was learned that her mother had similar lesions in the perianal region and on the hands. The father also had similar lesions in the perianal region and had been treated with cryotherapy. The child was also referred to the institutional committee of child neglect and abuse because of the initial impression of child abuse. The results were not suggestive for sexual abuse.

The patient was prepared for surgery with a two-day clear diet composed of only fluids without particles, and rectal enemas. The lesion was excised completely. First, an incision was made circumferentially around the peduncle of each lesion, and then the excision was preceded by cautery. The site of excision was then cauterized with diathermy. This sequence was repeated for each peduncle until the lesion was excised completely. Skin defects including previous biopsy site were closed in primary fashion with fine absorbable sutures (Fig. 3). The postoperative course was complicated with a small wound dehiscence, which was treated with local antibiotic pomade.

Discussion

Warts may be caused by many different types of HPV and are difficult to treat. Anogenital warts are especially important because of the

association between genital HPV infection and cervical carcinoma and the risk of child abuse³. In children, the mode of transmission of genital HPV is not only by sexual contact but also from mother to infant *in utero*, passage through an infected birth canal, or infection of a non-genital type virus to the genital area³. It is certain that HPV, especially types 16 and 18, is identified as an infectious agent in precancerous lesions and plays a role in the pathogenesis of cervical cancer⁵. It is also characterized by a high rate of local recurrences⁵. It has been reported that HPV types 6, 11, 16, and 18 may be associated with sexual transmission, and these children should be evaluated for sexual abuse^{2,3}. However, the current concept is that while the HPV type may give some clue regarding the likely mode of transmission, the virus type does not provide proof for the presence or absence of sexual abuse in children⁶. Additionally, routine typing study is not recommended in adults⁷.

In the present patient, the lesion was caused by HPV infection of types 6 and 18. Both parents had similar lesions at the same localizations, and the mother also had warts on her hands. The exact source of infection could not be determined in the present case. The source may be the lesion on her mother's hand, with the child being infected when the mother was giving care to the perianal region, or the child may have infected by vertical transmission. Sexual abuse must never be overlooked when

considering possible modes of transmission for perianal HPV, and the patient should be reported to an institutional child abuse evaluation group when any abuse is suspected. In the present case, the lesion was assumed as unrelated to sexual contact.

The primary goal of the treatment is to eliminate symptomatic warts. There is no ideal treatment modality for all patients or all kinds of warts. Recommended treatments include podophyllin solution or cream, imiquimod cream, trichloroacetic acid, bichloroacetic acid, cryotherapy, interferon, 5-fluorouracil, carbon dioxide laser, electrocautery, and surgery^{3,8}. Topical therapies may be painful, expensive or time-consuming. Repeated interventions to the anogenital region can predispose to psychological disturbance in an infant and may affect adversely the emotional status of the parents. Additionally, the large size of the lesion may increase the risk of dose-related adverse effects of the topical drugs. Surgical excision is a prompt solution to the problem. Surgery may be cheaper than other treatments and provides tissue diagnosis⁷. Furthermore, carcinoma *in situ* or dysplasia has been reported in association with CA in adults⁹.

Biopsy can be performed for initial tissue diagnosis. Primary surgery can be performed without initial biopsy if the physical examination was satisfactory for definition of the lesion. Total excision should be preferred in giant CA, especially when the lesion obstructs the

urethra or anal canal. Surgery should also be an alternative mode of treatment when the topical treatment fails in small CA. Superficial incisions should be made around the stalk of papillary lesions and then lesions should be excised totally. The lesion may invade into deep tissues. The surgeon should be sure that deep extensions have also been excised in those cases. The complications are not expected to be serious. In an adult series of 41 patients, surgical excision resulted in bleeding in 22% and discharge from the wound in 10% without infection, no extensive reconstruction, and no anal stenosis development or requirement of additional surgery later⁹. On the other hand, anal stricture following excision of CA in an infant has also been reported². We recommend that skin defects should be closed properly to achieve the best cosmetic result. Primary suture closure should be preferred in small defects. Larger defects can be closed by flaps or grafts⁵. It is usually not necessary to divert the fecal stream preoperatively. We recommend clear diet and rectal enemas for prevention of contamination by intestinal content during surgery.

The recurrence rate after surgical clearance of anal condylomata has been reported to be 25% in a large adult series, and HPV type 11 was found associated with higher recurrence rate (41%). Recurrences occurred within 21 to 357 days, with a median of 120 days⁷. The recurrence rate after laser treatment of CA was 23% in a group of children⁸.

Surgical excision should be treatment of choice in giant CA encountered in children. Surgery may also be used when topical treatment fails or delay in treatment occurs because of an uncooperative parent. The patient should be examined carefully for signs of sexual abuse and associated warts in other skin areas. Additionally, family members and caregivers should be evaluated for similar lesions. If there is evidence or suspicion of sexual abuse, the patient and family should undergo a complete social and medico-legal evaluation in this regard. This case illustrates that giant perianal CA may occur by extragenital contact from the parent to the child without the presence sexual abuse, and successful treatment is possible with total excision.

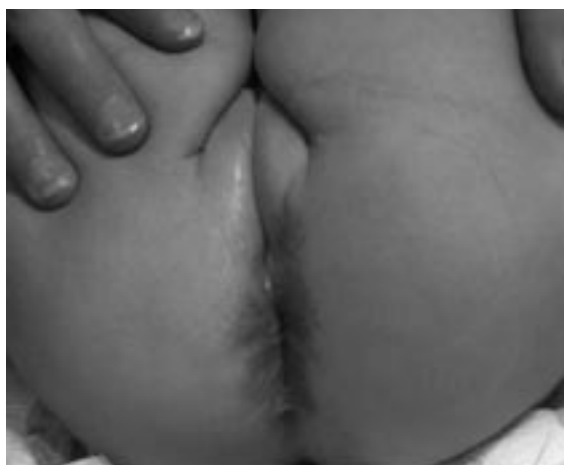

Fig. 3. The appearance of the perineum after completion of surgery.

REFERENCES

1. Tinsa F, Gharbi A, Essit A, et al. Giant condyloma acuminatum in an infant. *Pediatr Dermatol* 2011; 26: 488-489.
2. Schneider A, Lacreuse I, Moog R, et al. Buschke-Löwenstein anal tumor in children: two case reports. *Eur J Pediatr Surg* 2011; 19: 328-340.
3. Gruber PC, Wilkinson J. Successful treatment of perianal warts in a child with 5% imiquimod cream. *J Dermatol Treat* 2001; 12: 215-217.
4. Ambriz-Gonzales G, Escobedo-Zavala LC, Carrillo MF, et al. Buschke-Löwenstein tumor in childhood: a case report. *J Pediatr Surg* 2005; 40: E25-27.
5. Mestrovic T, Cavcic J, Martinac P, et al. Reconstruction of skin defects after radical excision of anorectal giant condyloma acuminatum: 6 cases. *J EADV* 2003; 17: 541-545.
6. Padel AF, Venning VA, Evans MF, et al. Human papilloma viruses in anogenital warts in children: typing by in situ hybridization. *BMJ* 1990; 300: 1491-1494.
7. D'Ambrogio A, Yerly S, Sahli R, et al. Human papilloma virus type and recurrence rate after surgical clearance of anal condylomata acuminata. *Sex Transm Dis* 2011; 36: 536-540.
8. Johnson PJ, Mirzai TH, Bentz ML. Carbon dioxide laser ablation of anogenital condyloma acuminata in pediatric patients. *Ann Plast Surg* 1997; 39: 578-582.
9. Klaristenfeld D, Israelit S, Beart RW, et al. Surgical excision of extensive anal condylomata not associated with risk of anal stenosis. *Int J Colorectal Dis* 2008; 23: 853-856.