

## Endobronchial tuberculosis complicated with staphylococcus aureus pneumonia and empyema in a child

Nevin Uzuner<sup>1</sup>, Özden Anal<sup>1</sup>, Özkan Karaman<sup>1</sup>, Can Sevinç<sup>2</sup>, Mehmet Türkmen<sup>1</sup>  
Tülay Canda<sup>3</sup>, Eyüp Kazan<sup>4</sup>

From the Departments of <sup>1</sup>Pediatrics, <sup>2</sup>Pulmonology, <sup>3</sup>Pathology and <sup>4</sup>Cardiothoracic Surgery, Dokuz Eylül University Faculty of Medicine, İzmir, Turkey

**SUMMARY:** Uzuner N, Anal Ö, Karaman Ö, Sevinç C, Türkmen M, Canda T, Hazan E. Endobronchial tuberculosis complicated with Staphylococcus aureus pneumonia and empyema in a child. Turk J Pediatr 2003; 45: 254-257.

Childhood tuberculosis might have unusual clinical presentation. A seven-year-old female patient was admitted with fever and pleural effusion. Her pneumonia resolved following 21-day treatment period. An atelectatic appearance remained on the right middle zone in her chest X-ray. Tuberculin skin test showed 13 mm induration. Triple drug antituberculosis treatment was started. Since atelectasis persisted on her follow-up radiograph one month later, bronchoscopy was performed which revealed a hemorrhagic polypoid mass occluding the right upper lobe anterior segment orifice. Surgical removal was performed by right upper lobectomy. The pathological diagnosis was necrotizing granulomatous infection suggesting tuberculosis. The patient has been well on follow-up after completing a nine-month course of antituberculous treatment.

*Key words:* endobronchial tuberculosis, pneumonia, child.

Endobronchial tuberculosis (EBTB) is regarded as a complication of progressive primary tuberculosis<sup>1</sup>. EBTB may cause respiratory symptoms such as atelectasis or secondary pneumonia. Clinical and radiological findings of bronchial obstruction are helpful in diagnosis. If diagnosis is delayed, EBTB may result in bronchial stenosis<sup>2</sup>. In countries where tuberculosis infection is prevalent, an endobronchial mass lesion should readily raise the suspicion of tuberculosis even in an apparently healthy child.

### Case Report

A 7-year-old female patient presented with high fever, coughing and right lateral chest pain. The complaints of coughing and high fever dated back to one month before. She was treated with oral antibiotics and antipyretics with diagnosis of respiratory tract infection. Her complaint recurred after a 10-day treatment period, and parenteral ceftriaxone was started four days before she was referred. History revealed a previously healthy child, and there was no contact with a known tuberculosis case. She had received

Bacille Calmette-Guérin (BCG) vaccine at three months of age.

At physical examination, the patient appeared pale and restless. Weight and height were at 10-25<sup>th</sup> percentiles. Axillary temperature was 39.5°C. Breath sounds were decreased on right side of chest. A few crackling rales could be heard. There were dullness on percussion. Posteroanterior (PA) chest radiograph showed a homogeneous density in right lung fields. Right pleural effusion and a loss of lung volume were present (Fig. 1). Computerized tomography (CT) of thorax demonstrated massive pleural effusion on right side and collapse in right upper lobe (Fig. 2). Pleural effusion had empyematous appearance. Gram and acid-fast staining, and all cultures of pleural fluid were negative. Staphylococcus aureus was grown only in blood culture.

The patient was treated with vancomycin and ceftriaxone along with closed chest tube drainage. Control chest radiographs demonstrated improvement although the atelectatic appearance persisted in right middle zone. A human immunodeficiency virus (HIV) screen by Western blot was negative. Mantoux

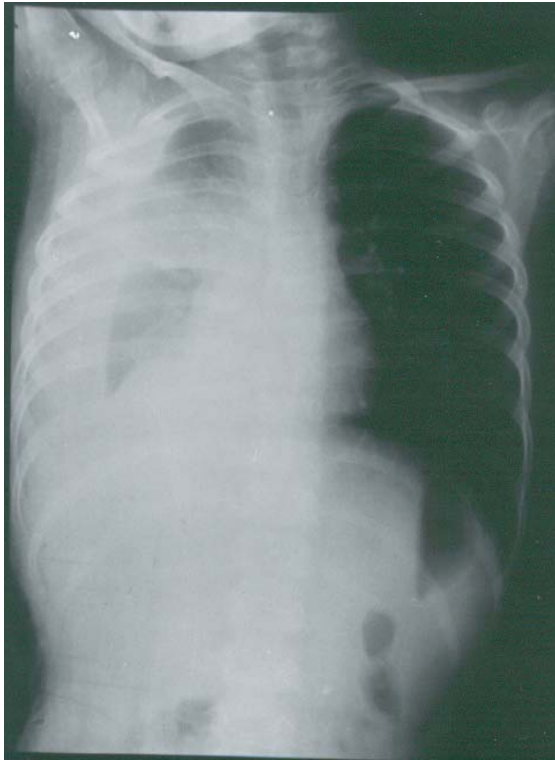


Fig. 1. Chest radiograph at admission.

testing with human tuberculin revealed a 13 mm/induration, and antituberculosis treatment with isoniazid, rifampicin and pyrazinamide was commenced.

Two months following the presentation of the patient, there was no resolution in the radiological appearance (Figs. 3, 4). Three consecutive morning gastric aspirates did not yield growth of tuberculosis bacilli.

Bronchoscopy demonstrated a smooth, shiny polypoid mass obliterating the upper lobe entrance of the right mainstem bronchus (Fig. 5). Bronchial washings failed to reveal any bacteriologic or cytologic result. Biopsy findings of the mass lesion were reported as nonspecific inflammation. Since the atelectasis had not resolved following two months of antituberculosis treatment, she underwent a diagnostic thoracotomy, and right upper lobectomy was performed. At the operation, right upper lobe was atelectatic, and pleural adhesions and peribronchial, perihilar enlargement of lymph nodes were noted. Histopathological evaluations of lymph

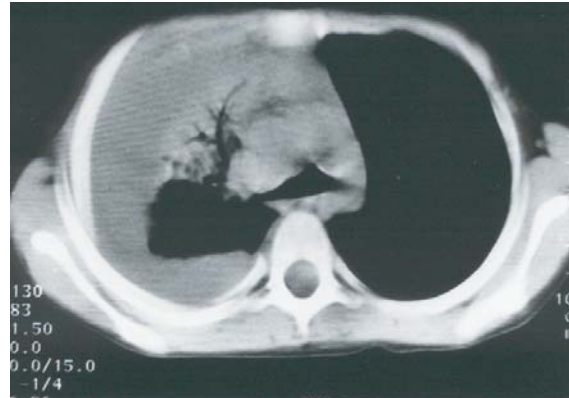


Fig. 2. Chest computerized tomography (CT) scan at admission.

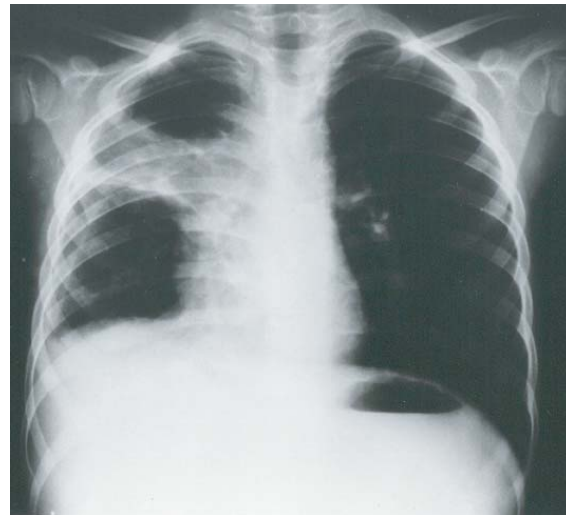

Fig. 3. Chest radiograph following two months of antituberculous treatment.

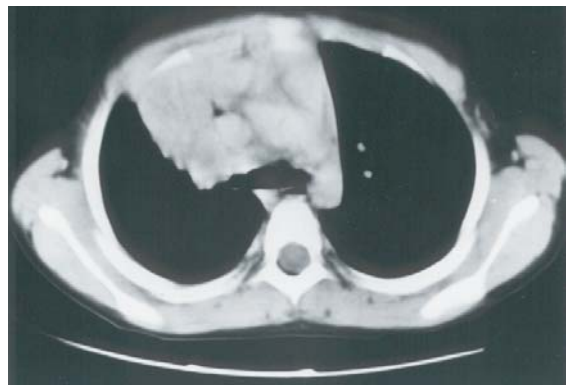

Fig. 4. Chest computerized tomography (CT) scan, mediastinal window following two months of antituberculous treatment.

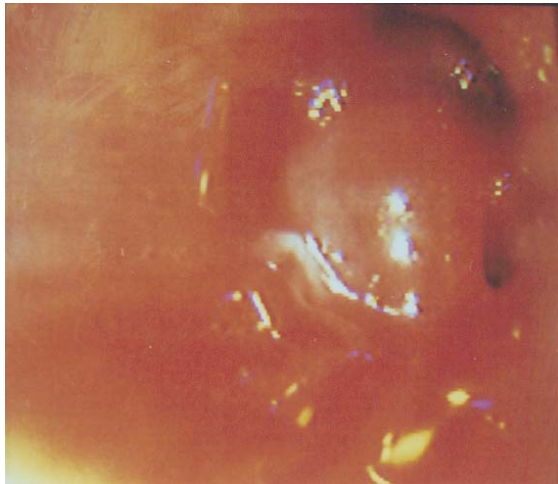


Fig. 5. Bronchoscopic view of a polypoid mass nearly occluding the upper lobe entrance of the right mainstem bronchus.

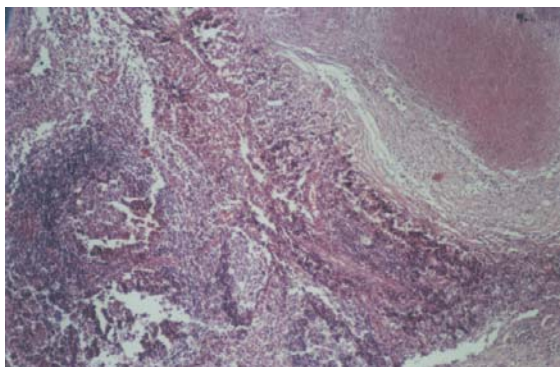


Fig. 6. Lobectomy specimen showing granuloma formation with central caseification and chronic inflammatory infiltration of the peripheral lung tissue.

node and lobectomy specimens demonstrated necrotizing granulomatous inflammation compatible with tuberculosis (Fig. 6). Direct examination and culture did not reveal tuberculous bacilli in the specimens.

Clinical and radiological examination of the patient has been normal on follow-up, with the patient having completed a nine-month course of antituberculosis treatment.

### Discussion

This patient was a complicated case of endobronchial tuberculosis for whom invasive procedures were needed to establish the diagnosis. Clinical, radiological and laboratory findings at presentation were suggestive of nonspecific pneumonia and parapneumonic

pleurisy. Later, persistent clinical and radiological findings of community-acquired pneumonia and positive tuberculin skin test raised the suspicion of tuberculosis, considering the high prevalence of this infection in Turkey. Bacteriologic assessment of pleural fluid and early morning gastric aspirates did not yield positive results. In this patient, bronchoscopy was undertaken as the diagnostic procedure. Endobronchial tumor, foreign body and bronchial stenosis were also considered for the differential diagnosis of EBTB. The mass was reported to be fragile and hemorrhagic. Lobectomy was performed later both for diagnostic and therapeutic reasons. This endobronchial obstructive lesion, in which granulomatous inflammation along with caseification were demonstrated histopathologically, and the positive tuberculin skin test were evaluated as tuberculosis disease although it was not proven bacteriologically. Staphylococcus aureus pneumonia complicated with empyema had developed distally to the lesion that obstructed the upper right lobe bronchus almost completely. The delay in resolution of this endobronchial obstruction was considered as an alarming finding leading to the differential diagnosis of tuberculosis.

Endobronchial tuberculosis is considered a result of lymphatic spread from a primary parenchymal infection or of rupture of an infected lymph node through the bronchial wall. As the bronchial wall is eroded by inflammation, the enlarged regional lymph nodes cause air trapping, atelectasis and stenosis of airways. Mucosal ulceration and development of granulation tissue frequently obstruct the right middle lobe bronchus. Either atelectasis or hyperaeration due to check valve obstruction develops<sup>3,4</sup>. Antituberculous treatment should not be delayed in order to prevent the development of such forms in primary pulmonary tuberculosis.

Chan et al.<sup>5</sup> analyzed bronchoscopic findings of 36 children with pulmonary tuberculosis, and found endobronchial involvement in 15 (41.7%). There was no clinical or radiological evidence of endobronchial disease in 10 of the patients. The value of flexible fiberoptic bronchoscopy as a reliable method in diagnosing EBTB has been emphasized by this study as well as recently by Chung et al.<sup>6</sup>

Hsu et al.<sup>7</sup> reported 32 endobronchial tuberculosis cases who were treated surgically

Segmental resection or lobectomy was performed in 13 cases along with bronchoplasty, and pulmonary resection alone was performed in 19 cases. The authors suggested surgical treatment as a safe method in EBTB with poor response to specific chemotherapy. In the present case surgery made the histopathological diagnosis of tuberculosis possible, and prevented development of complications of chronic atelectasis bronchiectasis or further recurrence of pneumonic infections.

Park et al.<sup>8</sup> demonstrated in their study on 34 patients with EBTB that the use of corticosteroids in addition to antituberculous treatment did not prevent bronchostenosis, and that early commencement of antituberculous drugs before the development of fibrosis would be effective in preventing the complications. Dore et al.<sup>9</sup> suggested addition of corticosteroids to the treatment of children with significant bronchial obstruction due to atypical mycobacterial infection.

Endobronchial tuberculosis (EBTB) can also be misdiagnosed as bronchial asthma, lymphoma, Hodgkin's disease, unresolving pneumonia or foreign body aspiration in childhood<sup>10,11</sup>.

In conclusion, bronchoscopic evaluation should be considered in cases of pneumonia in which resolution is delayed. Endobronchial mass lesions in children residing in countries with

high prevalence of tuberculosis infection should include the appropriate differential diagnosis of the disease, including invasive procedures when needed, in order to start effective treatment early and prevent further complications.

#### REFERENCES

1. Smith LS, Schillaci RF, Sarlin RF. Endobronchial tuberculosis. Serial fiberoptic bronchoscopy and natural history. *Chest* 1987; 91: 644-647.
2. Hoheisel G, Chan BK, Chan CH, Chan KS, Teschler H, Costabel U. Endobronchial tuberculosis: diagnostic features and therapeutic outcome. *Respir Med* 1994; 88: 593-597.
3. Matthews JJ, Matarese SL, Carpenter JL. Endobronchial tuberculosis simulating lung cancer. *Chest* 1984; 86: 642-644.
4. Inselman LS, Kendig EL. Tuberculosis. In: Chernick V, Boat TF, Kendig EL (eds). *Kendig's Disorders of the Respiratory Tract in Children* (6<sup>th</sup> ed). Philadelphia: WB Saunders Co; 1998: 883-934.
5. Chan S, Adabco DL, Steiner P. Role of flexible fiberoptic bronchoscopy in the diagnosis of childhood endobronchial tuberculosis. *Pediatr Infect Dis J* 1994; 13: 506-509.
6. Chung HS, Lee JH. Bronchoscopic assessment of the evolution of endobronchial tuberculosis. *Chest* 2000; 117: 385-392.
7. Hsu HS, Hsu WH, Huang BS, Huang MH. Surgical treatment of endobronchial tuberculosis. *Scand Cardiovasc J* 1997; 31: 79-82.
8. Park IW, Choi BW, Hue SH. Prospective study of corticosteroid as an adjunct in the treatment of endobronchial tuberculosis in adults. *Respirology* 1997; 2: 275-281.
9. Dore ND, LeSouef PN, Masters B, et al. Atypical mycobacterial pulmonary disease and bronchial