

## Management of central diabetes insipidus with oral desmopressin in a patient with ectrodactyly and cleft lip/palate (ECP) syndrome

Eda Özaydın<sup>1</sup>, Zehra Aycan<sup>2</sup>, Arzu Meltem Yusufoglu<sup>1</sup>, Ergun Çetinkaya<sup>2</sup>, Saime Ergen<sup>1</sup> Sevim Ünal<sup>3</sup>, Gülşen Köse<sup>4</sup>

Divisions of <sup>2</sup>Pediatric Endocrinology, <sup>3</sup>Neonatology and <sup>4</sup>Pediatric Neurology, <sup>1</sup>Ankara Dışkapı Children's Hospital, Ankara, Turkey

**SUMMARY:** Özaydın E, Aycan Z, Yusufoglu AM, Çetinkaya E, Ergen S, Ünal S, Köse G. Management of central diabetes insipidus with oral desmopressin in a patient with ectrodactyly and cleft lip/palate (ECP) syndrome. Turk J Pediatr 2009; 51: 89-93.

We present a female infant with facial abnormalities such as bilateral cleft lip and palate, ectrodactyly and central diabetes insipidus. She had a history of recurrent hypernatremic attacks and she was treated successfully with oral desmopressin. As an alternative to the nasal route, long-term management was achieved using oral route and she had a favorable growth and development during infancy.

**Key words:** ectrodactyly and cleft lip/palate (ECP) syndrome, central diabetes insipidus, desmopressin.

Desmopressin acetate (DDAVP) has been in clinical use for the treatment of central diabetes insipidus (CDI) since its introduction in 1972<sup>1</sup>. Nasal administration is the usual route. There are few reports of its oral use in neonates and infants<sup>2,3</sup>. We describe a female patient with ectrodactyly, cleft lip/palate (ECP) syndrome<sup>4</sup> and central diabetes insipidus, which has not been reported before. She was successfully treated with oral desmopressin.

### Case Report

An eight-day-old female infant was hospitalized because of indirect hyperbilirubinemia and hypernatremic dehydration. The infant was born weighing 2600 g at 40 weeks of gestation by normal spontaneous vaginal route without complication. She was the only child of healthy, young unrelated parents. Her mother took no drug during an uneventful pregnancy. On admission, the patient's weight was 2350 g, length 50 cm, head circumference 30.5 cm, body temperature 36.7°C, pulse rate 146/min, respiration rate 42/min and blood pressure 58/34 mmHg. Physical examination disclosed bilateral cleft lip and palate, bilateral low-set

ears, ocular hypertelorism, abnormal palpebral slant, microcephaly (Fig. 1A), ectrodactyly (lobster claw deformity with tetrasyndactyly) (Fig. 2A, B), and cephalhematoma. The remainder of the physical examination was



**Fig. 1a.** Her appearance at 2 months old (before surgery).

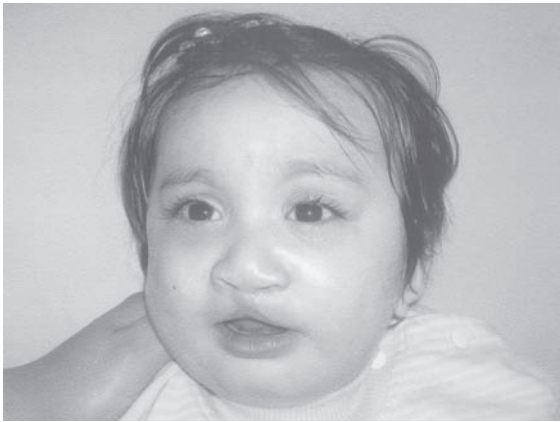

Fig. 1b. Her appearance at 14 months old (after surgery).

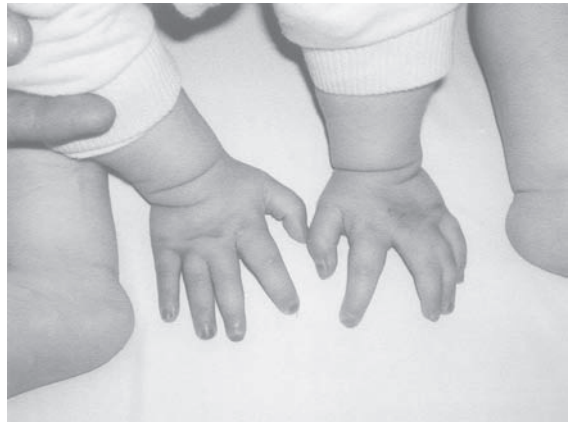

Fig. 2a. View of the hands.

normal. Her laboratory analysis revealed hypernatremia and indirect hyperbilirubinemia. Her sodium and glucose levels were increased, at 178 mEq/L and 214 mg/dl, respectively. Intravenous hydration and phototherapy were started. After treatment, she was discharged from the hospital.

Five days later, the patient was re-admitted to our hospital because of fever and hypernatremic dehydration. Her sodium level was 174 mEq/L. During follow-up, she had fever and thrombocytopenia and was treated with antibiotics due to suspected sepsis. *Escherichia coli* was isolated from blood cultures. Owing to the syndromic appearance, we performed chromosome analyses, which revealed 46 XX. Serum and urine amino acid profile and tandem mass spectrometry were found normal. Sweat chloride test was normal. Her immunoglobulin levels were in normal range. Abdominal ultrasonography showed bilateral enlargement of kidney pelvicaliceal structure, and voiding cystography was normal. Cranial tomography showed left parietal hemorrhage.

Despite her elevated sodium level, her appearance and performance had no correlation with a thirsty baby. After improvement of sepsis, she had unexplained elevated body temperature of 39°C. Her urine output was as high as 5.5 ml/kg/h. Diabetes insipidus was clinically suspected but water deprivation test was not performed because of the risk of severe dehydration. Her laboratory investigations were obtained at the beginning of the desmopressin test. The data were as follows: Na 174 mEq/L, blood urea nitrogen (BUN) 14 mg/dl, creatinine

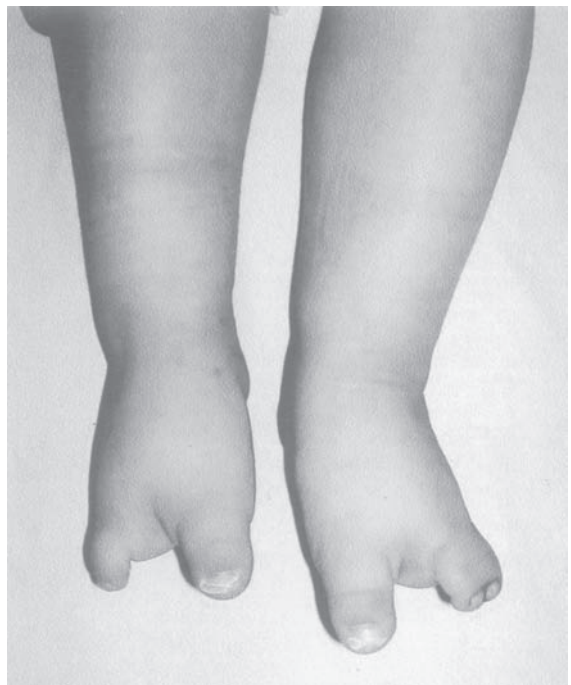

Fig. 2b. View of the feet.

0.5 mg/dl, serum osmolality 371 mOsm/kg, and urine osmolality 176 mOsm/kg. Complete blood count revealed Hb: 10.9 g/dl, Htc: 32.7%, WBC: 14300, platelet count 207,000/mm<sup>3</sup>, urinalysis pH: 5, specific gravity 1005, and 2-3 leukocytes in the sediment. Desmopressin acetate 2.5 µg/kg (Minirin tablet, 89 µg, powdered and prepared in oral suspension) was given with nasogastric feeding tube because of abnormal nasopharyngeal anatomy. Desmopressin administration caused a decrease in urine flow and increase in urinary concentration and osmolality (urinary

density 1005 to 1030, osmolality from 160 to 620 mOsm/kg). The results of the test supported the diagnosis of central diabetes insipidus (Table I). Oral desmopressin 2.5 µg/kg/day was started twice a day as the initial dose. Serum sodium levels decreased to normal levels (Fig. 3). The drug was continued with 5 µg/day as the total dose. The maintenance of the same dose of desmopressin controlled the fluid balance and serum electrolytes. Her electrolyte levels have remained normal after 12 months of treatment.

Magnetic resonance imaging (MRI) of the brain revealed lack of the physiological posterior pituitary hyperintense signal and thickening of the pituitary stalk. Anterior hypophysis diameter was 3 mm and hormone research showed: Total T3: 2.24 ng/ml (0.7-1.79), Total T4: 10.4 µg/dl (4.5-12.5), free T4: 0.96 ng/dl (0.8-1.9), TSH: 4.21 IU/ml (0.4-4.0), FSH: 0.22 mIU/L (2.8-11.3), LH: 0 mIU/L (1.9-11.6), ACTH: 23.3 pg/ml (3-46), cortisol 17.7 µg/dl (35), growth hormone (GH): 7.96 ng/ml (0.06-5), prolactin level 25.1 ng/ml

(1.9-25), and antidiuretic hormone (ADH): 0.15 pg/ml. Thyrotropin-releasing hormone (TRH) stimulation test supported the diagnosis of subclinical hypothyroidism. Peak thyroid-stimulating hormone (TSH) response to TRH stimulation was found as 35 IU/ml, and 5 µg/kg thyroxin therapy was started.

At 13 months of age, the cleft lip and palate was repaired by the Plastic Surgery Department (Fig. 1B). She is now 14 months old and has normal mental and motor development. Her weight, height and head circumference are at the 5<sup>th</sup>, 10<sup>th</sup> and 50<sup>th</sup> percentiles, respectively, for 12 months.

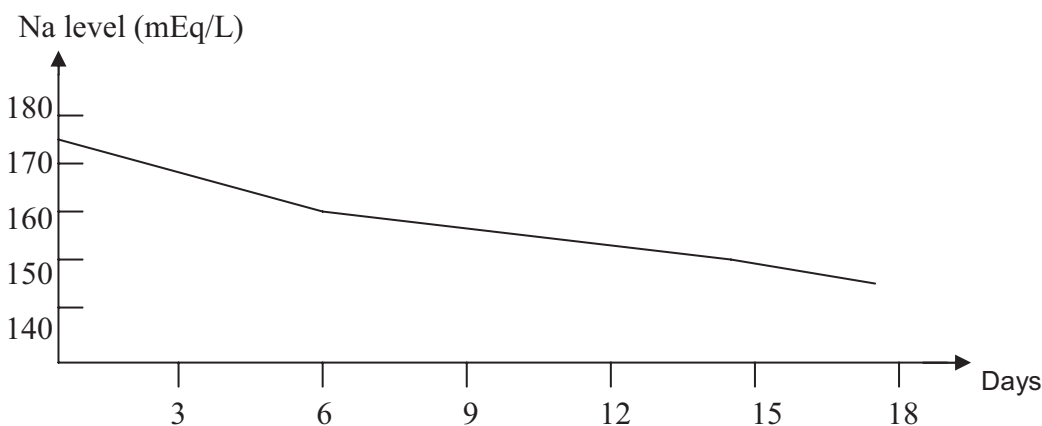
**Discussion**

We present a case with bilateral cleft lip and palate, ectrodactyly, microcephaly and central diabetes insipidus who was treated successfully with oral desmopressin.

Central diabetes insipidus is a heterogeneous disorder characterized by polyuria and polydipsia due to a deficiency of arginine vasopressin

**Table I.** Laboratory Values Before and After Oral Desmopressin Administration

	Before treatment	After treatment	14 months
Serum Na (mEq/L)	179	144	142
Serum osmolality (mOsm/kgH <sub>2</sub> O)	371	310	300
Urine specific gravity	1005	1030	1020
Urine osmolality (mOsm/kgH <sub>2</sub> O)	176	620	630
Urine volume (ml/kg/h)	5.5	2.8	-
Urine volume (24h, ml)	400	190	-
Serum glucose (mg/dl)	130	85	99



**Fig. 3.** Serum Na levels by days after oral desmopressin.

(AVP) secretion from the posterior gland. Various problems may lead to CDI, but central nervous system (CNS) malformations are frequently the most common etiology<sup>5</sup>. Midline brain anatomic abnormalities such as septo-optic dysplasia (SOD) and holoprosencephaly are occasionally related with anterior pituitary hormone deficiencies, while they are infrequently associated with CDI<sup>6</sup>.

Midline defects (e.g. cleft lip/palate, SOD) have been repeatedly described in association with isolated GH deficiency, isolated gonadotropin deficiency or multiple pituitary deficiencies<sup>7</sup>. König et al.<sup>8</sup> reported a male patient with holoprosencephaly, bilateral cleft lip/palate and ectrodactyly. Our case did not have holoprosencephaly but she had cleft lip and palate, which might lead to CDI. Although anterior hypophysis diameter was small in our patient, the hormone levels were found normal except thyroid hormones. TRH stimulation test supported the diagnosis of subclinical hypothyroidism.

The vicinity of the palate, the hypothalamic-pituitary centers and optic nerves may explain how all three structures can sometimes be affected during development, as has been demonstrated in experimental animals<sup>9</sup>. The association of these abnormalities with limb deformities is difficult to understand.

One of the causes of hypernatremia is hypodipsia-hypernatremia, and its association with median structure malformations of the brain and face is known<sup>10</sup>. Our patient had polyuria and fever, which suggest water deprivation, but lack of thirst. There is a close communication among neural centers regulating thirst and water conservation, and midline maldevelopment of the CNS may occasionally manifest with symptoms of disordered thirst in association with impaired ADH secretion<sup>11</sup>. Adipsia-hypodipsia and recurrent hypernatremia are usually manifestations of structural abnormalities of the hypothalamic-pituitary area. MRI of our patient revealed an absence of the posterior pituitary bright spot, which suggests interruption of the neurohypophyseal-pituitary communication, and this supports the diagnosis of DI<sup>12</sup>. The management of hypernatremia with DDAVP is also another finding supporting DI diagnosis in our patient.

Another interesting feature of our case is ectrodactyly (Fig. 2), which is the congenital absence of all or part of one or more fingers

or toes. It may be sporadic or a part of a hereditary disorder called the EEC syndrome (ectodermal dysplasia, ectrodactyly, cleft lip/palate), which is an autosomal dominant dysplasia syndrome, whose pleiotropic effects involve mainly ectodermal structures. The most common clinical manifestations are ectodermal dysplasia, ectrodactyly, cleft lip/palate and tear-duct anomalies. Very rarely, the ectrodactyly may be absent, and skeletal abnormalities may be subtle. Sankhyan et al.<sup>13</sup> reported a 44-month-old girl who had features of EEC syndrome but without the classic ectrodactyly. Our patient had syndactyly in the left hand and ectrodactyly in both feet, but she had no features of ectodermal dysplasia. Such phenotypical similarities may be attributed to the fact that there are common links in the pathogenesis of the syndromes; more genetic investigations should be done.

Gershoni-Baruch et al.<sup>14</sup> reported two brothers with EEC syndrome, hypogonadotropic hypogonadism and a small pituitary gland, and suggested that hypothalamopituitary insufficiency be accepted as another manifestation of the EEC syndrome. Since their cases were born to young, nonconsanguineous and unaffected parents, this report reconfirms that EEC syndrome is a pleiotropic trait with reduced penetrance and variable expressivity.

Lewis and Pashayan<sup>15</sup> reported two half-sibs with ectrodactyly and clefting, suggesting autosomal dominant inheritance. Rodini<sup>16</sup> reported a Brazilian boy with ectrodactyly and cleft lip/palate. The clinical signs observed in these patients suggest the existence of a clinical entity without ectodermal involvement. Since the extensive study of isolated and familial cases with EEC syndrome by Rodini et al. failed to demonstrate cases without ectodermal involvement, they concluded that these patients represent the same clinical entity, which is different from the EEC syndrome, termed as the ECP syndrome<sup>4</sup>. They suggested that the ECP syndrome is an autosomal dominant inherited disease with incomplete penetrance. Our patient is also the first child of a healthy unrelated couple, and one of the two parents seems to be an asymptomatic gene carrier.

London<sup>17</sup> presented a patient with fully expressed, sporadic EEC syndrome with renal involvement. The present case had a history of recurrent urinary tract infections (UTI); her abdominal ultrasonography showed bilateral enlargement

of kidney pelvicaliceal structure and voiding cystography was normal. She received antimicrobial prophylaxis for prevention of UTIs.

Oral desmopressin seems to be useful in maintaining normal plasma electrolyte concentration, weight gain and growth in the treatment of CDI during the first year of life. It is as safe and successful as other routes, although there are few reports of its oral use in neonates and infants in the literature. We also want to emphasize the importance of hypothalamic-pituitary endocrine investigation in patients with midline craniofacial malformation.

#### REFERENCES

1. Andersson KE, Arner B. Effects of desmopressin, a synthetic analogue of vasopressin, in patients with cranial diabetes insipidus. *Acta Med Scand* 1972; 192: 21-27.
2. Stick SM, Betts PR. Oral desmopressin in neonatal diabetes insipidus. *Arch Dis Child* 1987; 62: 1177-1178.
3. Atasay B, Berberoglu M, Gunlemez A, et al. Management of central diabetes insipidus with oral desmopressin in a premature neonate. *J Pediatr Endocrinol Metab* 2004; 17: 227-230.
4. EEC syndrome. In: Lachman RS (ed). *Taybi and Lachman's Radiology of Syndromes, Metabolic Disorders, and Skeletal Dysplasias* (5<sup>th</sup> ed). Philadelphia: Mosby, Elsevier; 2007: 231-232.
5. Santiprabhob J, Likitmaskul S, Boonyasiri A, Boonsathorn S, Buddawong T. Etiologies of central diabetes insipidus in Thai children. *J Pediatr Endocrinol Metab* 2005; 18: 653-661.
6. NG PC, Lee CH, Fok TF, et al. Central diabetes insipidus in a newborn with deletion of chromosome 7q. *J Paediatr Child Health* 1997; 33: 343-345.
7. Maldergen LV, Gillerot Y, Vamos E, Toppet M, Watillon P, Vliet GV. Vasopressin and gonadotropin deficiency in a boy with the ectrodactyly-ectodermal dysplasia-clefting syndrome. *Acta Paediatr* 1992; 81: 365-367.
8. König R, Beeg T, Tariverdian G, Scheffer H, Bitter K. Holoprosencephaly, bilateral cleft lip and palate and ectrodactyly: another case and follow up. *Clin Dysmorphol* 2003; 12: 221-225.
9. Couly G, Le Douarin NM. The fate map of the cephalic neural primordium at the presomitic to the 3 somite stage in the avian embryo. *Development* 1988; 103 (Suppl): 101-113.
10. Schaad U, Vassella F, Zuppinger K, Oetliker O. Hypodipsia-hypernatremia syndrome. *Helv Paediatr Acta* 1979; 34: 63-76.
11. Karabay-Bayazit A, Herguner O, Altunbasak S, Noyan A, Yuksel B, Anarat A. Hypodipsia-hypernatremia syndrome associated with holoprosencephaly in a child: a case report. *Turk J Pediatr* 2002; 44: 263-266.
12. Bode HH, Crawford JD, Danon M. Disorders of antidiuretic hormone homeostasis. Diabetes insipidus and SIADH. In: Lifshitz F (ed). *Pediatric Endocrinology*. New York: Marcel Dekker, Inc; 1996: 731-751.
13. Sankhyan N, Kaushal RK, Sanin S. Ectodermal dysplasia, ectrodactyly, cleft lip/palate syndrome without ectrodactyly. *Dermatol Online J* 2006; 12: 5.
14. Gershoni-Baruch R, Goldscher D, Hochberg Z. Ectrodactyly-ectodermal dysplasia-clefting syndrome and hypothalamo-pituitary insufficiency. *Am J Med Genet* 1997; 68: 168-172.
15. Lewis MB, Pashayan HM. Ectrodactyly, cleft lip and palate in two half sibs. *J Med Genet* 1981; 18: 394-396.
16. Rodini ES, Freitas JA, Richie-Costa A. Ectrodactyly, cleft lip/palate syndrome. *Am J Med Genet* 1991; 38: 539-541.
17. London R, Heredia RM, Israel J. Urinary tract involvement in EEC syndrome. *Am J Dis Child* 1985; 139: 1191-1193.