

## Cerebral vasculitis and obsessive-compulsive disorder following varicella infection in childhood

Ahmet Yaramış<sup>1</sup>, Sabri Hergüner<sup>2</sup>, Bülent Kara<sup>3</sup>, Burak Tatlı<sup>4</sup>  
Ümran Tüzün<sup>2</sup>, Meral Özmen<sup>3</sup>

<sup>1</sup>Department of Pediatrics, Dicle University Faculty of Medicine, Diyarbakır, <sup>2</sup>Department of Pediatrics, Kocaeli University Faculty of Medicine, Kocaeli, and <sup>3</sup>Departments of Pediatric Neurology, and <sup>4</sup>Child and Adolescent Psychiatry, İstanbul University İstanbul Faculty of Medicine, İstanbul, Turkey

**SUMMARY:** Yaramış A, Hergüner S, Kara B, Tatlı B, Tüzün Ü, Özmen M. Cerebral vasculitis and obsessive-compulsive disorder following varicella infection in childhood. *Turk J Pediatr* 2009; 51: 72-75.

Varicella is largely a childhood disease, with more than 90% of cases occurring in children younger than 10 years. The primary infection is characterized by generalized vesicular dermal exanthemas, which are extremely contagious. Secondary bacterial infection and varicella pneumonia, usually seen in the immunocompromised or adult populations, may have high morbidity and mortality. Varicella in childhood is a generally benign and self-limited disorder; however, severe, life-threatening neurological complications may occur. We report a previously healthy eight-year-old boy who presented with acute hemiplegia and obsessive-compulsive disorder secondary to a lesion in lentiform nuclei associated with a history of recent varicella infection. The child was treated with sertraline for obsessive-compulsive disorder symptoms and made a full recovery.

**Key words:** central nervous system, child, obsessive-compulsive disorder, primary varicella, vasculitis.

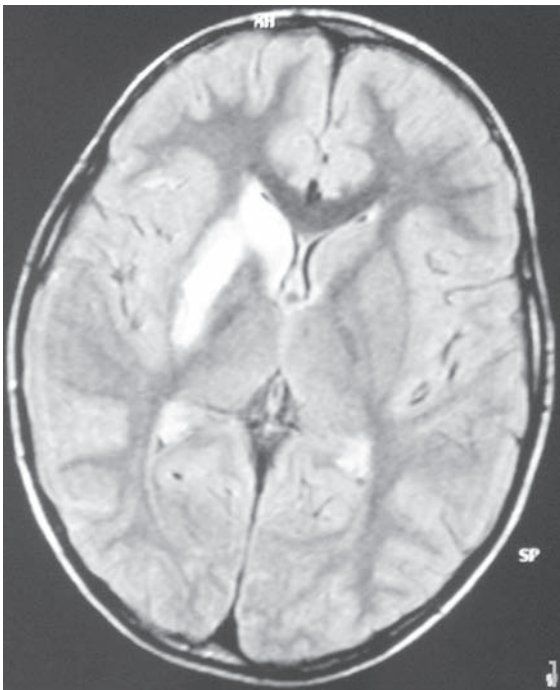
Neurological complications caused by varicella are estimated as approximately 0.01%-0.03%<sup>1,2</sup>. Primary varicella infection and varicella-zoster virus (VZV) reactivation can both cause central nervous system (CNS) vasculitis, and varicella-related strokes are well known in children<sup>3</sup>. They can involve large and small arteries, and usually present with hemiparesis in children<sup>4</sup>. Choreoathetosis due to basal ganglia infarction after varicella infection was noted in one pediatric case<sup>5</sup>.

Herein, we report a child who presented with acute hemiplegia and obsessive-compulsive disorder (OCD) secondary to basal ganglia lesion after varicella infection.

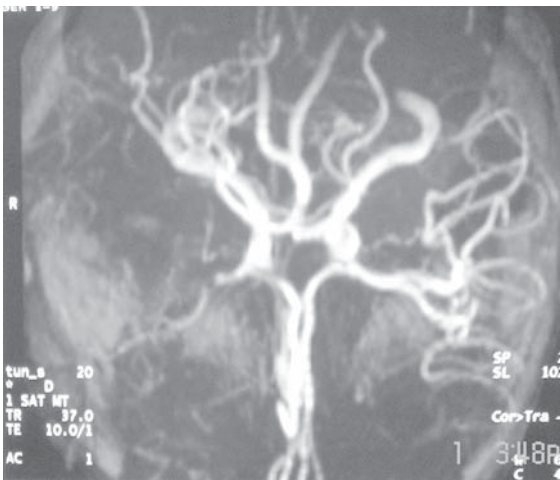
### Case Report

An eight-year-old boy was admitted to the child neurology clinic with headache and minimal weakness in the left extremities for two days. His medical history was unremarkable except for varicella infection three months before admission.

On examination, his temperature was 38°C, pulse: 78 beats per minute, and blood pressure: 108/79 mmHg. He had minimal weakness, hyperactive deep tendon reflexes and an extensor plantar response on the left arm and leg. Complete blood count and routine biochemistry were normal. Magnetic resonance imaging (MRI) of the brain disclosed an infarct involving the right thalamus and extending to the putamen (Fig. 1a). Magnetic resonance angiography (MRA) revealed severe narrowing of the M1 segment of the right middle cerebral artery (MCA) (Fig. 1b). Cerebrospinal fluid (CSF) analysis was acellular with normal glucose, protein and lactate concentration, no oligoclonal bands and negative bacterial cultures. VZV immunoglobulin G was found positive in serum and CSF by enzyme-linked immunoassay (EIA). Coagulation profile, including prothrombin time, activated partial thromboplastin time, fibrinogen, anti-thrombin III, protein C, protein S, lipoprotein A, serum homocysteine level,



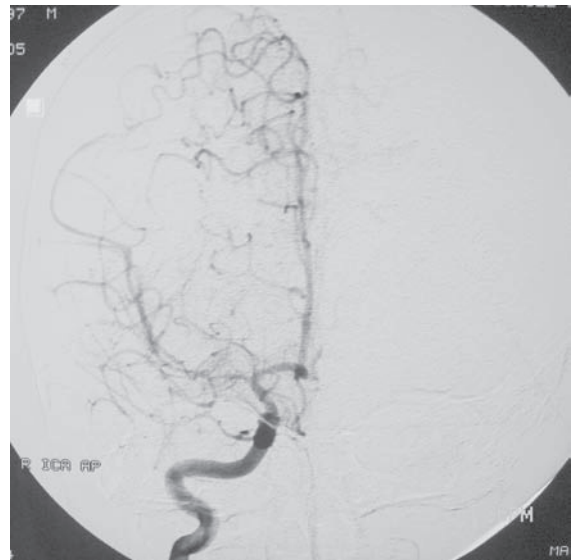
**Fig. 1a.** Proton-weighted axial magnetic resonance image (TR/TE/; 3000/22ms) shows an infarct involving the right caudate nucleus extending to the putamen.



**Fig. 1b.** Magnetic resonance angiography revealed severe narrowing and irregularity of the M1 segment of right middle cerebral artery.

and anticardiolipin antibodies, was normal. Factor V Leiden mutation and prothrombin gene polymorphism were absent. Complement profile was normal and anti-nuclear, anti-DNA antibodies, anti-nuclear core antigen, rheumatoid factor, and C-reactive protein were negative. Electrocardiography and echocardiography were normal.

A conventional cerebral angiography was performed to rule out thrombosis. It showed stenosis of the M1 segment of the right MCA, segmental narrowing on the M2 segment of the right MCA and right posterior cerebral artery (PCA) with irregular vessel walls, typical for vasculitis (Fig. 1c). The patient was discharged at the end of the first week, after complete resolution of symptoms without any treatment.



**Fig. 1c.** Digital subtraction cerebral angiography (DSA) shows stenosis in the M1 and M2 segments of the right middle cerebral artery.

Two months later, he presented with compulsive and intermittent aggressive behavior. Compulsions involved repetitive checking and erasing his writings on his notebooks numerous times throughout the day, totalling some 1-2 hours per day. The symptoms were uncontrollable and interfered seriously with daily life; he was unable to go to school and do homework. The compulsion subtotal score on the Yale Brown Obsessive Compulsive (YBOC) scale was 13/20 and consistent with a compulsive behavior while the obsession subtotal score was 0/20<sup>6</sup>. He was diagnosed as OCD according to the Diagnostic and Statistical Manual of Mental Disorders (DSM)-IV criteria<sup>7</sup>. His IQ scores on Wechsler Intelligence Scale-Revised (WISC-R) were 103 on the verbal test, 104 on the performance test, and 104 full scale.

A combination of behavioral therapy and pharmacotherapy with sertraline 25 mg per day was started, to be increased up to 100 mg

gradually according to the severity of symptoms. Clinical improvement was observed in the third month of the treatment and the dose was tapered gradually over three months. He returned to school and routine daily life.

### Discussion

In 1999, Sébire et al.<sup>8</sup> demonstrated a significant statistical association between “idiopathic” arterial strokes in childhood and varicella. The pathogenesis is controversial. It can be due to vasculopathy resulting from damage to the vessel wall media by direct viral invasion, immune complex reactions, or both. Direct viral spread may occur via trigeminal nerve or sympathetic nerves or the hematogenous pathway<sup>9,10</sup>. On the other hand, reports of stroke after immunization for varicella support the role of autoimmune mechanisms.

Varicella vasculopathy can involve large vessels<sup>11</sup>, less frequently small vessels<sup>12</sup>, or both<sup>13</sup>. It can manifest weeks to months after varicella; however, a latency period up to four years has been reported<sup>14</sup>. The mean interval between the onset of varicella and the neurologic disorder is two months<sup>15,16</sup>. The interval between the infection and the onset of the stroke in our patient was three months.

In our case, MRI, MRA, and conventional cerebral angiography disclosed an infarct involving the right thalamus and extending to the putamen, loss of signal from the supraclinoid portion of the right ICA and M1 segment, stenosis of the right M1 segment, and segmental narrowing of M2 and PCA segments with irregular vessel walls.

This case was of interest because of the compulsive symptoms associated with basal ganglia infarction. Although most OCD cases can not be related to any brain disease or focal lesion, OCD may be encountered after basal ganglia lesions of various etiologies<sup>17</sup>. The more frequent occurrence of bilateral caudate nucleus lesions to induce OCD was illustrated by Croisile et al.<sup>19</sup>. These authors reported a case who suffered two ischemic strokes of the caudate nucleus with a two-month interval between them. The patient presented transient apathy after the first stroke but the second contralateral lesion resulted in persistent compulsive disorder. Unilateral ischemic stroke of the putamen

and ischemia or progressive atrophy of the caudate nucleus have been associated with OCD<sup>18,19</sup>. The pathophysiology of OCD after basal ganglia lesions remains speculative but is probably due to a dysfunction of the fronto-striatal loops, which are responsible for frontal deafferentation, and consequently to a lack of inhibition of automatic behavior<sup>20</sup>. While OCD after varicella vasculopathy affecting basal ganglia has not been reported before to our knowledge, attention deficit and tic disorders have been reported after varicella encephalitis localized to the basal ganglia<sup>21</sup>.

Our case is the first to demonstrate behavioral disorder following varicella-related stroke in this region.

### Acknowledgements

We thank Professor Banu Anlar, Department of Pediatric Neurology, Hacettepe University Faculty of Medicine, Ankara, for valuable advice and critical review of the manuscript.

### REFERENCES

- Gnann JW. Varicella-zoster virus: atypical presentations and unusual complications. *J Infect Dis* 2002; 186: 91-98.
- Shiihara H. Neurological complications of varicella-zoster virus (VZV) infection. *No To Hattatsu* 1993; 25: 128-134.
- Askalan R, Laughlin S, Mayank S, et al. Chickenpox and stroke in childhood: a study of frequency and causation. *Stroke* 2001; 32: 1257-1262.
- Ganesan V, Kirkham FJ. Mechanisms of ischaemic stroke after chickenpox. *Arch Dis Child* 1997; 76: 522-525.
- Silverstein FS, Brunberg JA. Postvaricella basal ganglia infarction in children. *Am J Neuroradiol* 1995; 16: 449-452.
- Scahill L, Riddle MA, Mcswiggin-Hardin M, et al. Children's Yale-Brown Obsessive Compulsive Scale: reliability and validity. *J Am Acad Child Adolesc Psychiatry* 1997; 36: 844-852.
- American Psychiatric Association Diagnostic and Statistical Manual of Mental Disorders (4<sup>th</sup> ed). Washington, DC: American Psychiatric Association Press, Inc; 1994.
- Sébire G, Meyer L, Chabrier S. Varicella as a risk factor for cerebral infarction in childhood: a case-control study. *Ann Neurol* 1999; 45: 679-680.
- Linnemann CC Jr, Alvira MM. Pathogenesis of varicella-zoster angitis in the CNS. *Arch Neurol* 1980; 37: 239-240.
- Darling CF, Larsen MB, Byrd SE, Radkowski MA, Palka PS, Allen ED. MR and CT imaging patterns in post-varicella encephalitis. *Pediatr Radiol* 1995; 25: 241-244.
- Eda I, Takashima S, Takeshita K. Acute hemiplegia with lacunar infarct after varicella infection in childhood. *Brain Dev* 1983; 5: 494-499.

12. Kleinschmidt-Demasters BK, Amlie-Lefond C, Gilden DH. The patterns of varicella zoster virus encephalitis. *Hum Pathol* 1996; 27: 927-938.
13. Hayman M, Henderson G, Poskitt KJ, Connolly MB. Post-varicella angiopathy: report of a case with pathologic correlation. *Pediatr Neurol* 2001; 24: 387-389.
14. Melanson M, Chalk C, Georgevich L, et al. Varicella-zoster virus DNA in CSF and arteries in delayed contralateral hemiplegia: evidence for viral invasion of cerebral arteries. *Neurology* 1996; 47: 569-570.
15. Ichiyama T, Houdou S, Kisa T, Ohno K, Takeshita K. Varicella with delayed hemiplegia. *Pediatr Neurol* 1990; 6: 279-281.
16. Berger TM, Caduff JH, Gebbers JO. Fatal varicella-zoster virus antigen-positive giant cell arteritis of the central nervous system. *Pediatr Infect Dis J* 2000; 19: 653-656.
17. Kellner CH, Jolley RR, Holgate RC, et al. Brain MRI in obsessive-compulsive disorder. *Psychiatry Res* 1991; 36: 45-49.
18. Daniele A, Bartolomeo P, Cassetta E, et al. Obsessive-compulsive behaviour and cognitive impairment in a parkinsonian patient after left putaminal lesion. *J Neurol Neurosurg Psychiatry* 1997; 62: 288-289.
19. Croisile B, Tourniaire D, Confavreux C, Trillet M, Aimard G. Bilateral damage to the head of the caudate nuclei. *Ann Neurol* 1989; 25: 313-314.
20. Laplane D, Levasseur M, Pillon B, et al. Obsessive-compulsive and other behavioural changes with bilateral basal ganglia lesions. A neuropsychological, magnetic resonance imaging and positron tomography study. *Brain* 1989; 112: 699-725.
21. Dale RC, Church AJ, Heyman I. Striatal encephalitis after varicella zoster infection complicated by Tourettism. *Mov Disord* 2003; 18: 1554-1556.