

Visceral childhood leishmaniasis in southern Turkey: experience of twenty years

Oğuz Dursun¹, Seyhan Erişir², Akif Yeşilipek³

Divisions of ¹Intensive Care, ²Neonatology, and ³Hematology, Department of Pediatrics, Akdeniz University Faculty of Medicine, Antalya, Turkey

SUMMARY: Dursun O, Erişir S, Yeşilipek A. Visceral childhood leishmaniasis in southern Turkey: experience of twenty years. Turk J Pediatr 2009; 51: 1-5.

One hundred and one children with visceral leishmaniasis (VL) who admitted to Akdeniz University Hospital during a 20-year period were analyzed. Median age of the patients was 3 years (range: 5.5 months-13 years). The most common symptoms at presentation were fever, pallor and abdominal distension. Splenomegaly was found in all of the patients while hepatomegaly was present in 98%. Anemia (96%), leukopenia (74%) and thrombocytopenia (56%) were the main laboratory abnormalities. Thirty-three (33%) of the patients were pancytopenic on admission. Bone marrow smear was positive for leishmania in 91% of the patients. Seventy-four patients were treated with antimony ± pentamidine and 27 with amphotericin B. Three of our patients died because of secondary infections and hemorrhage. Relapse was observed in two patients. No patient showed post kala-azar dermal leishmaniasis findings.

We conclude that VL should be considered in patients with prolonged fever, hepatosplenomegaly and cytopenia who live in an endemic region. Amphotericin B is a therapeutic agent as effective as pentavalent antimony compounds and could be preferred.

Key words: visceral leishmaniasis, kala-azar, splenomegaly, hepatomegaly, dyserythropoiesis.

Leishmania is a protozoan parasite that causes visceral, cutaneous or mucocutaneous leishmaniasis in humans. It is estimated that approximately 12 million people are currently infected and a further 350 million are at risk of acquiring leishmaniasis in 88 countries¹. In Turkey, *Leishmania infantum* is responsible for human visceral leishmaniasis (VL), also called kala-azar. Dogs are considered to be the main reservoir and *Phlebotomus sergenti*, *P. papatasi* as well as *P. major* are considered to be the probable vectors of the disease in the Aegean and Mediterranean regions².

Fever, pallor, wasting, hepatomegaly and massive splenomegaly are typical in VL. Jaundice, edema and ascites may be present³. Anemia, leukopenia or thrombocytopenia, elevated hepatic transaminase levels and hypergammaglobulinemia are characteristic. If left untreated, it can produce cachexia, bleeding from thrombocytopenia, susceptibility to secondary infections and death⁴.

Direct visualization of amastigotes in the spleen, bone marrow, lymph node aspirate smears or liver biopsy is the gold standard for diagnosis of VL^{5,6}. Recently, direct agglutination test, immunofluorescent antibody test, ELISA and polymerase chain reaction (PCR) have been used for the serological and molecular diagnosis of VL⁷.

Parasite properties in addition to host factors and host responses regulate heterogeneous disease expression. Manifestations also vary by parasite species and endemic region⁴. Turkey is situated in the Mediterranean region, where leishmaniasis is endemic. However, there is no nationwide epidemiological research about the incidence of the disease. There are only a few reports of childhood leishmaniasis from Turkey^{2,5,8-10}. In the present study, clinical and laboratory findings of VL in our region were retrospectively analyzed and the response to two different treatment regimens was evaluated.

Material and Methods

The medical reports of Akdeniz University School of Medicine, Department of Pediatrics between 1984 and 2006 were analyzed retrospectively for diagnosis of VL. Akdeniz University Hospital is the single tertiary reference center in the region. The duration of the disease from the onset of signs and symptoms to diagnosis, demographic features, physical findings and laboratory results including complete blood count, peripheral blood and bone marrow smear examinations, liver function tests, hyperglobulinemia, and leishmania hemagglutination tests were obtained from medical records. Megaloblastic and dyserythropoietic changes in bone marrow aspiration smears were noted. At our center, the diagnosis of VL was based on clinical and laboratory features with direct visualization of the protozoon in bone marrow aspiration smears or liver biopsies and indirect hemagglutination tests. Splenic aspiration was avoided because of limited experience and risk of severe hemorrhage.

The prognosis and treatment-related side effects were compared between the treatment regimens, which included antimony \pm pentamidine or amphotericin B. Meglumine antimonate was used as 20 mg/kg per day for 30 days and pentamidine as 4 mg/kg 15 infusions every other day. Conventional amphotericin B was used as 1 mg/kg per day for 21 days, amphotericin B lipid complex as 3 mg/kg per

day for 5 days and liposomal amphotericin B as 3 mg/kg per day for 5 consecutive days, and the dosage was repeated on the 14th and 21st days.

Results

One hundred and one cases of VL were admitted to our hospital during a 20-year period. Young children were the most frequently affected population. The median age was 3 years (range: 5.5 months -13 years), and 48 (47%) of the patients were female. The mean duration of the disease from the onset of signs and symptoms to diagnosis was 41 days (range: 7-90 days). The majority of the patients were living in the rural regions of the cities of Antalya, Burdur, Isparta and Mugla (86%). On admission, the most common symptoms were fever (99%), pallor (89%) and abdominal distension (67%). Splenomegaly was observed in all and hepatomegaly in 98% of the patients. Anemia (96%), leukopenia (74%) and thrombocytopenia (56%) were the main laboratory abnormalities (Table I). Thirty-three (33%) of the patients were pancytopenic on admission. Leishmania hemagglutination test was positive in 57% (35 out of 61) of the patients and bone marrow aspiration was positive for leishmania in 91% (91 out of 101) of the patients (Fig. 1). In five patients whose clinical and laboratory findings were concordant with leishmaniasis but bone marrow aspirations were negative for leishmania amastigotes, liver biopsy was performed and Donovan bodies were seen in

Table I. Clinical and Laboratory Features of the Patients

	No. of cases	%
Signs and symptoms		
Fever	100/101	99
Abdominal distension	68/101	67
Pallor	90/101	89
Physical examination		
Splenomegaly	101/101	100
Hepatomegaly	99/101	98
Laboratory findings		
Anemia	97/101	96
Leukopenia	75/101	74
Thrombocytopenia	57/101	56
Pancytopenia	33/101	33
Hyperglobulinemia	33/38	86
Abnormal liver function tests	24/47	54
Positive leishmania hemagglutination test	35/61	57
Positive bone marrow aspiration	91/100	91
Positive liver biopsy	5/5	100

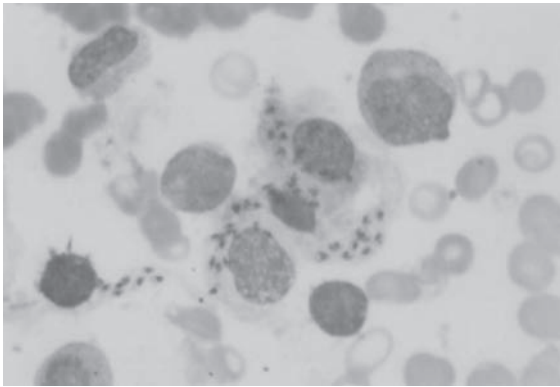


Fig. 1. *Leishmania* amastigotes in bone marrow smear.

all of them. One patient who was diagnosed and treated for VL four months before at another hospital admitted to our center with fever, pallor, abdominal distension, hepatosplenomegaly and pancytopenia. Although the serological tests and bone marrow aspiration were negative for leishmaniasis, he was accepted as relapse due to clinical and hematological findings. One patient whose brother had the same clinical findings and positive bone marrow aspiration and three patients who were from endemic areas and had the clinical findings of VL and dyserythropoietic and megaloblastic changes in their bone marrow smears were also accepted as VL. The clinical and laboratory findings of these four patients, whose bone marrow aspiration and liver biopsies revealed no leishmania amastigotes, resolved following antileishmanial therapy.

Seventy-four (73%) of our patients were treated with meglumine antimonate combined with pentamidine and 27 (27%) with amphotericin B. Conventional amphotericin B was given to 8 (8%), amphotericin B lipid complex to 4 (4%) and liposomal amphotericin B to 15 (15%) patients. Three of our patients who received meglumine antimonate combined with pentamidine therapy died because of secondary infections (bronchopneumonia) and hemorrhage. Relapse was observed in two patients in the meglumine antimonate – pentamidine combination group who were finally cured with a repeated therapy with the same drug combination. Patients who had evidence of secondary infections received appropriate antibiotics.

Discussion

The infectivity, pathogenicity and virulence of the leishmania parasites and host responses regulate the heterogeneous disease expression

and clinical manifestations; expression and manifestations vary still further by parasite species and endemic region⁴. This is the most definitive series in southern Turkey for VL according to clinical and laboratory findings, treatment response and complications. Limited series have been reported from other parts of Turkey^{2,8-10}. The most dramatic finding on physical examination is marked splenomegaly that may reach massive proportions and may lead to cytopenias³. In concordance with the literature, the most prominent features of our patients were splenomegaly (100%), fever (99%), anemia (96%) and hepatomegaly (98%). It was also noticed that anemia, leukopenia and thrombocytopenia were frequent laboratory abnormalities. Clinical findings of our series indicated that kala-azar should be suspected in endemic areas when patients present with enlarged spleen, pancytopenia (especially anemia), and hyperglobulinemia.

A definitive diagnosis depends on the demonstration of amastigotes in tissue or the isolation of promastigotes in culture¹¹. Splenic aspiration, which is considered an invasive method, provides the highest yield (positive in >80% of cases) and is safe, but is generally avoided by inexperienced physicians³. It has been used for routine diagnosis in the field, for example in Kenya and Sudan¹². Splenic aspiration was avoided in our center because of the risk of severe complications and our limited experience. Bone marrow aspiration is well known as the second most sensitive procedure (54-86% positive), and it was positive in 91 of the patients (91%) in our study. Liver biopsy may also be helpful for diagnosis and in some series it reached up to 70% positivity. However, it was required in only five (5%) out of 101 cases, because most of the patients in our study were easily diagnosed by bone marrow aspiration examination³.

We also noticed that megaloblastic and dyserythropoietic changes were prominent in most of the bone marrow smears of the patients, as shown in a previous study, and all of those findings disappeared after antileishmanial therapy¹³ (Fig. 2).

Even though the possibility of demonstrating amastigotes by bone marrow aspiration or liver biopsy is high, in some cases, diagnosis can not be achieved by these methods. Although these

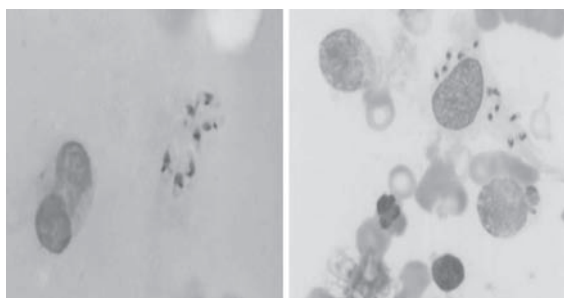


Fig. 2. Dyserythropoiesis and leishmania amastigotes in bone marrow aspirate.

tests were negative for leishmaniasis in five patients who were from areas endemic for kala-azar, they were given antileishmanial therapy based on history and clinical and laboratory findings. All the clinical and laboratory findings of those five patients resolved after the therapy. According to our experiences, we suggest that in those circumstances, empiric therapy can be used in endemic areas.

Leishmania hemagglutination test was performed in 61 patients and was positive in only 35 (57%). According to our series, due to its low sensitivity, it is not reasonable to recommend the test as a diagnostic tool for childhood VL in surveillance studies.

Treatment approaches and responses to chemotherapy also vary by region. The pentavalent antimonial compounds sodium stibogluconate and meglumine antimonate have been the preferred drugs for treating leishmaniasis, and these were the main treatment regimens in our center before the clinical usage of amphotericin B³. Common side effects of these compounds include abdominal pain, anorexia, vomiting, nausea, myalgia, arthralgia, headache and malaise, but these complications infrequently lead to cessation of the therapy. Pentamidine is another effective, but toxic, alternative. Side effects are frequent and include headache, flushing, vomiting, nausea, abdominal discomfort, hypoglycemia, and vascular collapse when the drug is infused too rapidly. Conventional amphotericin B deoxycholate is also active against leishmania species. Its use has been limited because of nephrotoxicity and other side effects and requires parenteral administration over a prolonged period. Liposomal amphotericin B recently became the first and only drug approved by the U.S. Food and Drug Administration for

the treatment of VL. It is at least as effective as, and less toxic than, pentavalent antimony. Although the data are limited, amphotericin B lipid complex also appears to be effective¹¹. Seventy-four (74%) of our patients were treated with meglumine antimonate plus pentamidine. All of our patients responded well initially. However, relapse was observed in two patients and they were subsequently cured with the same combination therapy. Conventional amphotericin B was given to eight, amphotericin B lipid complex to four and liposomal amphotericin B to 15 patients. They all responded well and no relapse was observed. Fever and chills were seen in two patients in the amphotericin B lipid complex group. The therapy of one patient in the conventional amphotericin B group was switched to liposomal amphotericin B because of hypokalemia due to renal tubulopathy.

Death may result from bacterial pneumonia, septicemia, tuberculosis, dysentery, or measles, or may be the consequence of malnutrition, severe anemia, or hemorrhage¹¹. The major complications leading to death, including hemorrhage and bacterial super-infection, result from a decrease in blood cells due to leishmanial infection of the bone marrow and hypersplenism³. It was also reported that secondary hemophagocytic lymphohistiocytosis could be seen in childhood VL, but it was seen in only one of our patients¹⁴. Three of our patients died because of pneumonia and hemorrhage due to thrombocytopenia.

Post kala-azar dermal leishmaniasis (PKDL) is a well-known complication of VL with unknown cause. A rash with tiny papules on the face resembling measles and papular lesions on a background of depigmented macules are the most common presentations. The reported frequency varies from 20% to 56%⁷. We could not find any data associated with PKDL in our series or in other reports in the literature from Turkey. We believe that it may also be implicated with host genetics or parasitological factors in this endemic region.

Although VL is not ranked among the leading infectious causes of the global burden of disease, it is a life-threatening disease of great medical, social, and economic importance in endemic areas¹². The number of patients who admitted to our center between 1984-1993 was

40 and between 1994-2006 was 61. These data indicate that there has been no decline in the number of cases and that VL remains a public health problem in the southern part of Turkey.

In conclusion, VL should be suspected in patients with prolonged fever, hepatosplenomegaly, anemia, leukopenia and thrombocytopenia living in areas endemic for leishmaniasis. Amphotericin B compounds can be used for the therapy, not only because of their high therapeutic effects but also due to the less significant side effects. VL is still a public health problem in south Turkey. Nationwide epidemiological studies to establish the incidence of the disease, early diagnosis and treatment, and elimination of sand fly vectors should be performed.

Acknowledgements

We kindly thank Ayfer Gur Guven MD, Olcay Yegin MD, Iffet Bircan MD, Halil Ertug MD, Sükran Tacoy MD, Nihal Oygur MD, Sema Akcurin MD, Reha Artan MD, Volkan Hazar MD, Senay Haspolat MD, Gayaz Akcurin MD, Sema Akman MD, Aysen Uguz MD, Sevtap Velipasaoglu MD, Firat Kardelen MD, and Alphan Kupesiz MD, from Akdeniz University Faculty of Medicine, Department of Pediatrics.

REFERENCES

1. WHO Fact Sheet (www.who.int/inf-fs/en/fact116.html).
2. Ok UZ, Balcioglu IC, Taylan OA, et al. Leishmaniasis in Turkey. *Acta Trop* 2002; 84: 43-48.
3. Melby PC. Leishmaniasis. In: Behrman RE, Kliegman RM, Jenson HB (eds). *Nelson Textbook of Pediatrics* (17th ed). Philadelphia: WB Saunders; 2000: 1130-1133.
4. Murray HW, Berman JD, Davies CR, et al. Advances in leishmaniasis. *Lancet* 2005; 366: 1561-1577.
5. Artan R, Yilmaz A, Akcam M, et al. Liver biopsy in the diagnosis of visceral leishmaniasis. *J Gastroenterol Hepatol* 2006; 21: 101-104.
6. Herwaldt BL. Leishmaniasis. *Lancet* 1999; 354: 1191-1199.
7. Osman OF, Kager PA, Oskam L. Leishmaniasis in Sudan: a literature review with emphasis on clinical aspects. *Trop Med Int Health* 2000; 5: 553-562.
8. Hicsonmez G, Ozsoylu S. Kala-azar in childhood: a survey of clinical and laboratory findings and prognosis in 44 childhood cases. *Clin Pediatr* 1972; 11: 465-467.
9. Ozensoy S, Ozbel Y, Turgay N, et al. Serodiagnosis and epidemiology of visceral leishmaniasis in Turkey. *Am J Trop Med Hyg* 1998; 59: 363-369.
10. Totan M, Dagdemir A, Muslu A, et al. Visceral childhood leishmaniasis in Turkey. *Acta Paediatr* 2002; 91: 62-64.
11. Pearson R.D, Queiroz SA, Jeronimo SM. Leishmania species: visceral (kala-azar), cutaneous, and mucosal leishmaniasis. In: Mandell GL, Bennett JE, Dolin R (eds). *Mandell: Principles and Practice of Infectious Diseases* (5th ed). Philadelphia: Churchill Livingstone; 2000: 2831-2841.
12. Guerin PJ, Olliaro P, Sundar S, et al. Visceral leishmaniasis: current status of control, diagnosis, and treatment, and a proposed research and development agenda. *Lancet Infect Dis* 2002; 2: 494-501.
13. Wickramasinghe SN, Abdalla SH, Kasili EG. Ultra structure of bone marrow in patients with visceral leishmaniasis. *J Clin Pathol* 1987; 40: 267-275.
14. Gurgey A, Secmeer G, Tavit B, et al. Secondary hemophagocytic lymphohistiocytosis in Turkish children. *Pediatr Infect Dis J* 2005; 24: 1116-1117.