

Prenatally diagnosed lethal type Larsen-like syndrome associated with bifid tongue

Diclehan Orhan¹, Sevim Balcı², Özgür Deren³, Eda Gülen Ütine²

Ahmet Başaran³, Gülsev Kale¹

Divisions of ¹Pediatric Pathology and ²Clinical Genetics, Department of Pediatrics, and ³Department of Obstetrics and Gynecology, Hacettepe University Faculty of Medicine, Ankara, Turkey

SUMMARY: Orhan D, Balcı S, Deren Ö, Ütine EG, Başaran A, Kale G. Prenatally diagnosed lethal type Larsen-like syndrome associated with bifid tongue. Turk J Pediatr 2008; 50: 395-399.

Larsen syndrome is characterized by multiple joint dislocations, associated with a typical facial appearance and frequently other abnormalities. Both dominant and recessive patterns of inheritance have been reported. A lethal form of Larsen syndrome (Larsen-like syndrome) has been described as a combination of the Larsen phenotype and pulmonary hypoplasia. In this report, we present a 24-week-old female fetus with a possible prenatal diagnosis of thanatophoric dysplasia in whom postmortem examination revealed lethal type Larsen-like syndrome associated with bifid tongue, severe micrognathia and non-immune hydrops fetalis. These findings have not been reported previously in the lethal type Larsen syndrome.

Key words: Larsen-like syndrome (lethal type), bifid tongue, multiple dislocations, severe micrognathia, prenatally diagnosed.

Larsen et al.¹ described a syndrome characterized by multiple joint dislocations and unusual facies in 1950. The most significant facial features included depressed nasal bridge with widely spaced eyes and a prominent forehead. Cleft palate, hydrocephalus, cardiac malformations and abnormalities of spinal segmentation have also been described^{2,3}. Autosomal dominant and autosomal recessive patterns of inheritance have been suggested. It is reported that different patterns of inheritance could be related to the clinical variability of this syndrome^{4,5}.

Chen et al.⁶ described a lethal variant of Larsen syndrome (Larsen-like syndrome) (OMIM 245650) characterized by multiple joint dislocations, tracheomalacia, lung hypoplasia and collagen abnormalities. In Larsen-like syndrome, death occurs shortly after birth with pulmonary insufficiency due to tracheomalacia and/or lung hypoplasia^{7,8}. Histochemical and electron microscopic studies showed abnormalities of cartilage matrix, collagen bundles of joint capsules and hyaline cartilage of the trachea^{6,9}. Previously, seven patients were reported to have Larsen-like syndrome,

including a sib-pair described by Mostello et al.¹⁰ suggestive of autosomal recessive inheritance^{6, 9,11-13}.

We present a 24-week-old aborted female fetus from a first-cousin marriage, further suggesting autosomal recessive inheritance. The fetus had Larsen-like syndrome (lethal type) with previously undefined bifid tongue. Bifid tongue, severe micrognathia and pulmonary hypoplasia could be responsible for the respiratory problems in Larsen-like syndrome, and every patient with Larsen-like syndrome should be examined carefully for the possibility of these abnormalities.

Case Report

A 23-year-old pregnant woman, gravida 3, para 1, was referred at 24 weeks' gestation because of sonographically detected fetal anomalies. The parents were first cousins. The first pregnancy resulted in a healthy male infant who was currently 6 years old, while the obstetric history of the couple was remarkable with regard to an infant who died on the first postpartum day, for which

the cause was obscure and necropsy was not available. Prenatal scan at the 24th week of this pregnancy revealed polyhydramnios, abnormal facial appearance, bilateral rocker bottom feet deformity, hyper-extended knees (genu recurvata) and abnormally short extremities (micromelia) (Fig. 1). Femoral and humeral

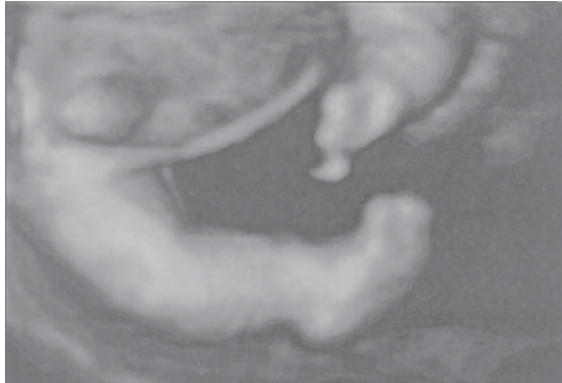


Fig. 1a. Prenatal ultrasonography photograph showing rocker bottom feet deformity and hyper-extended knee (genu recurvata).

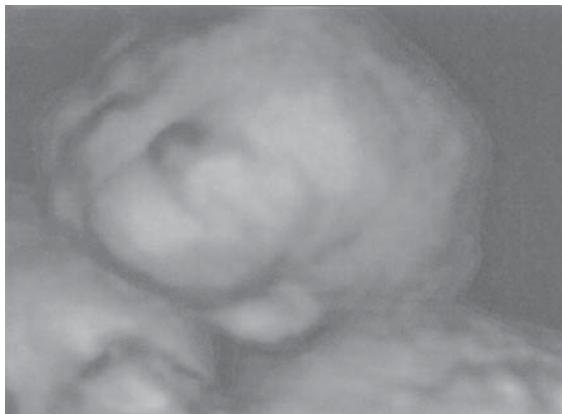

Fig. 1b. Prenatal ultrasonography photograph revealing abnormal facial appearance.

lengths were consistent with 21st week of gestation, whereas biparietal diameter and abdominal circumference were consistent with 27th and 26th weeks, respectively. Thoracic/abdominal circumference ratio was smaller than expected. Fetal echocardiogram revealed levocardia and moderate degree of tricuspid incompetence. Right atrium and right ventricle were larger than the corresponding left chambers of the heart. On clinical suspicion of a lethal form of short rib skeletal dysplasia, with a most likely diagnosis of thanatophoric dysplasia, the pregnancy was terminated after genetic counseling.

At autopsy, there was non-immune hydrops fetalis with nuchal edema, edematous feet and hands, with a fetal weight of 848 g (normal range, 510±79 g) (Fig. 2). Facial features included a prominent forehead, depressed nasal bridge and widely spaced eyes (Fig. 3). Additionally, severe

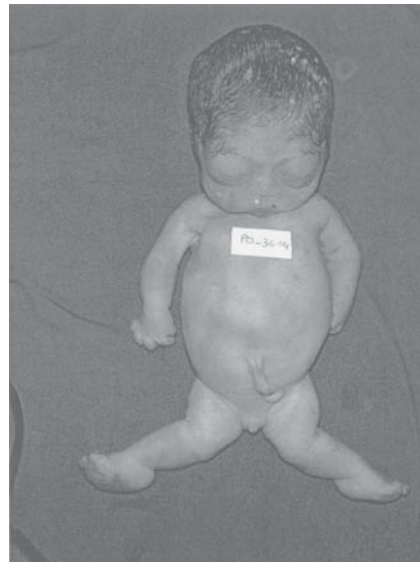

Fig. 2. Postmortem appearance of the fetus showing multiple joint dislocations, unusual facies and generalized edema.

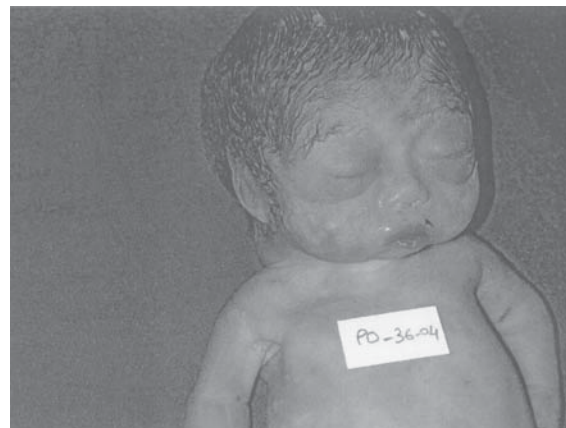

Fig. 3. Postmortem photograph of the fetus showing prominent forehead, depressed nasal bridge, widely spaced eyes and severe micrognathia.

micrognathia, bifid tongue and bilateral simian lines were easily recognized in postmortem examination (Figs. 3-5). Multiple joint dislocations were seen. The ratio of pulmonary weight to body weight was 0.009, consistent with pulmonary hypoplasia. Post-mortem radiographs showed multiple joint dislocations and a barrel-

shaped thorax (Fig. 6). Patella was present and there was no genitourinary abnormality. Microscopic examination revealed irregular growth plates and chondrocyte hyperplasia at the joints (Fig. 7). Cytogenetic analysis was performed on GTG-banded metaphase spreads prepared from phytohemagglutinin (PHA)-stimulated peripheral blood lymphocytes after standard culture and chromosome preparation techniques. Chromosome analysis was done in 20 metaphases with a resolution of 550 bands. Fetal karyotype was normal.

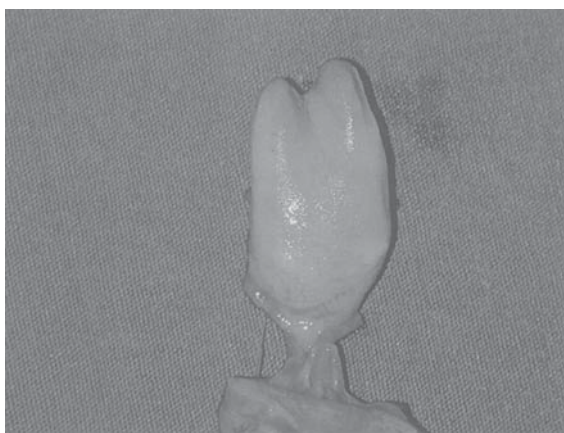


Fig. 4. Bifid tongue of the fetus.

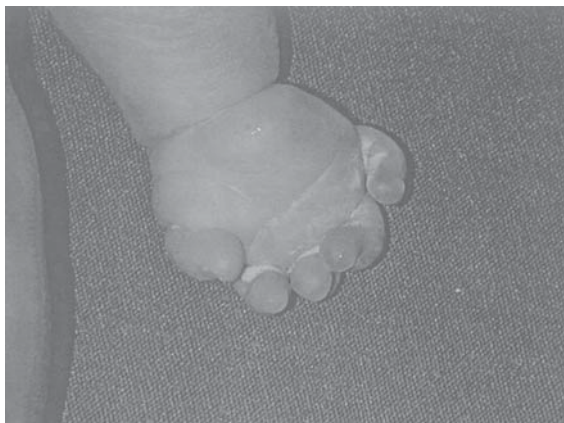

Fig. 5. Simian line of the fetus.

Discussion

Bilateral dislocation of knees, elbows and ankles, pulmonary hypoplasia and dysmorphic facial features including prominent forehead, depressed nasal bridge, and widely spaced eyes were suggestive of Larsen-like syndrome (the lethal variant of Larsen syndrome) in the presented fetus. This syndrome was first

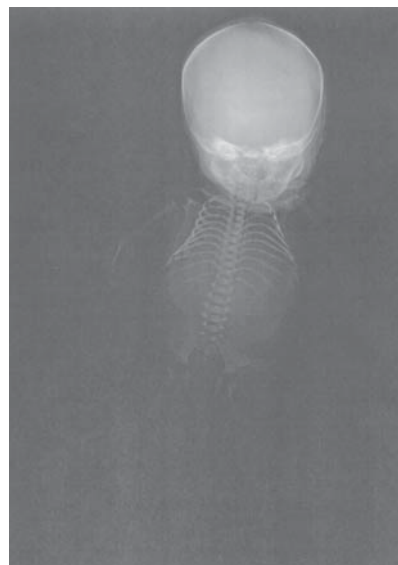


Fig. 6. Postmortem radiograph showing multiple joint dislocations and a hypoplastic thorax.

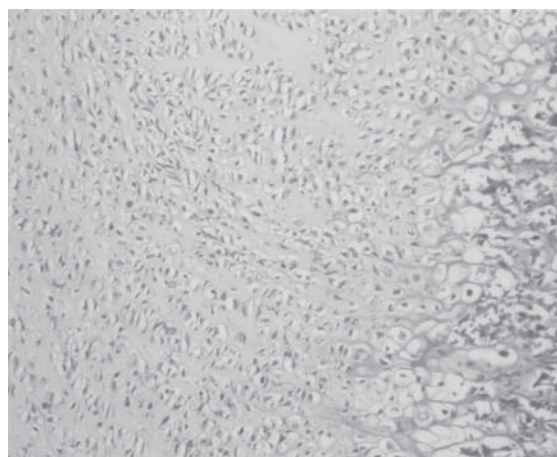


Fig. 7. Growth plate of the hip with chondrocyte hyperplasia and distortion of the cartilage columns.

reported by Chen et al.⁶ in 1982. Further cases were reported by Clayton-Smith and Donnai⁹, Mostello et al.¹⁰, and Caksen et al.¹³. Major findings useful in distinguishing these patients are neonatal death due to pulmonary hypoplasia, metaphyseal dysplasia and abnormal palmar creases. Pulmonary hypoplasia, irregular growth plates and chondrocyte hyperplasia at the joints in the present patient as well as the presence of bilateral simian lines were consistent with these distinguishing findings of the syndrome.

Multiple joint dislocations may be a feature in several syndromes. Among these are several skeletal dysplasias including pseudo-diastrophic dysplasia, certain types of spondyloepimetaphyseal dysplasia, pseudoachondroplasia and Larsen-like syndrome, all of which have unique discriminating features. Other syndromes with multiple joint dislocations are Marfanoid hypermobility syndrome in which the patients have tall stature, Lemieux-Neemeh syndrome in which the patients have associated nephritis, neuropathy and sensorineural deafness, tenascin X deficiency with predominating symptoms related to connective tissue, Matsoukas syndrome with associated mental and ocular abnormalities, and several types of Ehlers-Danlos syndrome. Multiple joint dislocations may also be observed in some types of cutis laxa syndromes and Desbuquois dwarfism. Atelosteogenesis type III, caused by mutations in the gene encoding filamin B, is also characterized by multiple joint dislocations¹⁴.

Larsen syndrome is characterized by joint hypermobility and multiple joint dislocations, especially of knees and feet¹. The characteristic facial features include midfacial hypoplasia with a depressed nasal bridge. Autosomal dominant and autosomal recessive forms of the condition have been proposed^{4,15,16}. The autosomal dominant Larsen syndrome is caused by heterozygous mutations in the gene encoding filamin B (FLNB)¹⁹. The reported patients with Larsen-like syndrome (OMIM 608545) had a mutation in a gene involved in collagen production, which is located either on chromosome 1q or, more likely, on 6p. Lethal type Larsen-like syndrome has significant clinical overlap with Larsen syndrome, particularly with common facial and articular findings; however, the condition is particularly distinct when pulmonary hypoplasia is considered. Mostello et al.¹⁰ provided the first evidence of recessive inheritance of the lethal variant of Larsen-like syndrome; however, the genetic abnormality of this syndrome is still unknown.

Presence of bifid calcaneus and extra carpal bones, fusion defects of cervical spine, dental anomalies, radio-ulnar synostosis and presence of bifid thumbs were previously reported in patients with Larsen syndrome^{15,16,20}. It is reported that patients with Larsen syndrome must be evaluated carefully before surgery as the laryngeal anomaly may collapse during the operation²¹.

Bifid tongue, which may be present in some short rib polydactyly syndromes and some types of orofaciocigital syndrome, was not previously described in Larsen or Larsen-like syndromes. The prevalence of bifid tongue among the Turkish pediatric population was reported as 0.4% in one series²². Genetic counseling is very important for recurrence of this syndrome. Early sonographic examination should diagnose this syndrome with skeletal deformity and congenital ductus aneurysm^{10,16-18}.

In conclusion, we present in this article a lethal type of Larsen-like syndrome in a 24-week-old female fetus with sonographic and postmortem findings. Interestingly, this fetus had midline cleft tongue (bifid tongue), which was not previously reported in these patients.

REFERENCES

1. Larsen LJ, Schottstaedt ER, Bost FC. Multiple congenital dislocations associated with characteristic facial abnormality. *J Pediatr* 1950; 37: 574-581.
2. Bowen JR, Otega K, Ray S, MacEwen GD. Spinal deformities in Larsen's syndrome. *Clin Orthop* 1985; 197: 159-163.
3. Le Marec B, Chapuis M, Treguier C, Odent S, Bracq H. A case of Larsen syndrome with severe cervical malformations. *Genet Couns* 1994; 5: 179-181.
4. Petrella R, Rabinowitz JG, Steinmann B, Hirschhorn K. Long-term follow-up of two sibs with Larsen syndrome possibly due to parental germ-line mosaicism. *Am J Med Genet* 1993; 47: 187-197.
5. Knoblauch H, Urban M, Tinschert S. Autosomal recessive versus autosomal dominant inheritance in Larsen syndrome: report of two affected sisters. *Genet Couns* 1999; 10: 315-320.
6. Chen H, Chang CH, Perrin E, Perrin J. A lethal, Larsen-like multiple joint dislocation syndrome. *Am J Med Genet* 1982; 13: 149-161.
7. Latta RJ, Graham CB, Aase J, Scham SM, Smith DW. Larsen's syndrome: a skeletal dysplasia with multiple joint dislocations and unusual facies. *J Pediatr* 1971; 78: 291-298.
8. Malik P, Choudry DK. Larsen syndrome and its anaesthetic considerations. *Pediatr Anesth* 2002; 12: 632-636.
9. Clayton-Smith J, Donnai D. A further patient with the lethal type of Larsen syndrome. *J Med Genet* 1988; 25: 499-500.
10. Mostello D, Hoechstetter L, Bendon RW, Dignan PS, Oestreich AE, Siddiqi TA. Prenatal diagnosis of recurrent Larsen syndrome: further definition of a lethal variant. *Prenat Diagn* 1991; 11: 215-225.
11. Yamaguchi K, Ogawa Y, Handa T. Brain dysplasia associated with Larsen-like syndrome. *Pediatr Neurol* 1996; 14: 75-79.
12. Kurtoglu S, Dundar M, Hallac IK, Uzum K, Okumus Y, Oktem T. Polycystic kidney disease, biliary dysgenesis in a patient with Larsen's syndrome. *Clin Genet* 1997; 51: 408-411.

13. Caksen H, Kurtoglu S. Larsen syndrome associated with severe congenital hydrocephalus. *Genet Couns* 2001; 12: 369-372.
14. Jones KL. *Smith's Recognizable Patterns of Human Malformation* (6th ed). Philadelphia: WB Saunders; 2006: 498-499.
15. Laville JM, Lakermance P, Limouzy F. Larsen's syndrome: review of the literature and analysis of thirty-eight cases. *J Pediatr Orthop* 1994; 14: 63-73.
16. Becker R, Wegner RD, Kunze J, Runkel S, Vogel M, Entezami M. Clinical variability of Larsen syndrome: diagnosis in a father after sonographic detection of a severely affected fetus. *Clin Genet* 2000; 57: 148-150.
17. Je BK, Yoo SY, Lee W, Kim WS, Kim IQ. Aneurism of the ductus arteriosus in a patient with Larsen syndrome. *Pediatr Radiol* 2006; 36: 1215-1218.
18. Tongprasert F, Tongsong T, Sittiwangkul R. Prenatal sonographic diagnosis of congenital ductus arteriosus aneurysm: a case report. *J Med Assoc Thai* 2005; 88: 541-544.
19. Krakow D, Robertson SP, King LM, Morgan T. Mutations in the gene encoding filamin B disrupt vertebral segmentation, joint formation and skeletogenesis. *Nat Genet* 2004; 36: 405-410.
20. Perçin EF, Gedik R, Develioğlu H, Kunt T. Larsen's syndrome with dental anomalies: report of a case. *ASDC J Dent Child* 2002; 69: 172-174.
21. Karakaş G, Perçin EF, Perçin S. Surgical risk factors in Larsen's syndrome. *Acta Orthop Belg* 2000; 66: 495-498.
22. Ugar-Cankal D, Denizci S, Hocaoglu T. Prevalence of tongue lesions among Turkish schoolchildren. *Saudi Med J* 2005; 26: 1962-1967.