

Lipofibromatosis in a two-year-old girl: a case report

Ayşegül Sarı¹, Mine Tunakan¹, Betül Bolat¹, Handan Çakmakçı², Erdener Özer³

¹Department of Pathology, Ataturk Training and Research Hospital, and Departments of ²Radiology and ³Pathology, Dokuz Eylul University Faculty of Medicine, Izmir, Turkey

SUMMARY: Sarı A, Tunakan M, Bolat B, Çakmakçı H, Özer E. Lipofibromatosis in a two-year-old girl: a case report. Turk J Pediatr 2007; 49: 319-321.

Lipofibromatosis is a recently described rare benign soft tissue tumor of childhood. We report a case of a lipofibromatosis in a two-year-old girl with a painless mass on the plantar aspect of her right foot who developed local recurrence eight months after surgery. The tumor has a high rate of non-destructive recurrence, but there is no metastatic potential. Complete surgical resection is the mainstay of treatment. Nevertheless, the rareness of its presentation should be taken into account by the pediatric pathologist, and considerable surgical judgment is of great importance.

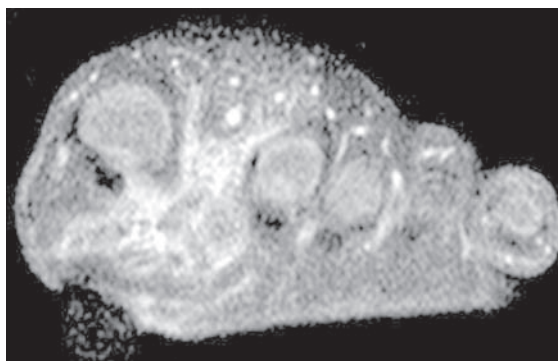
Key words: lipofibromatosis, children, soft tissue tumor.

Lipofibromatosis is a histologically distinctive and rare fibrofatty tumor of the pediatric age group with a predilection to involve distal extremities. It has only recently been described as a clinicopathologic entity, in 2000 by Fetsch et al.¹, and subsequently, to our knowledge, only four case reports have been published in the literature to date²⁻⁵. To address the clinicopathologic significance of this rare entity, we describe herein a case of lipofibromatosis occurring on the left foot of a child who presented with recurrence eight months later.

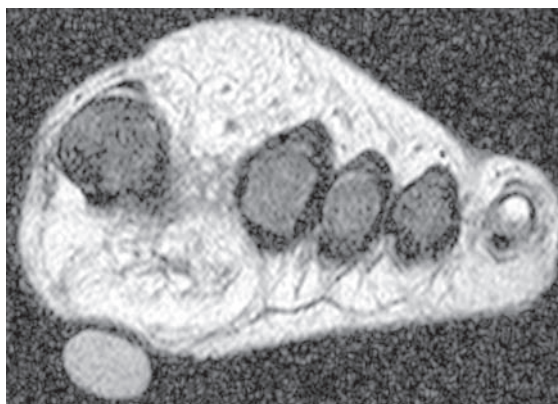Case Report

A two-year-old girl was admitted to the Department of Plastic Surgery with the complaint of a slowly growing painless mass on her right foot of nine-months' duration. Her medical and surgical histories were unremarkable. On physical examination, a solitary and firm mass (approximately 4x3 cm in size) was palpated on the right plantar region of her right foot. Magnetic resonance (MR) imaging showed a soft tissue mass in the inter-junction of the first and second right toes and extending to the metatarsal region (Fig. 1). The mass was removed surgically and sent for histological examination.

Macroscopic examination of the specimen showed a 4.5x2x1.5 cm, yellowish-gray, irregular soft and rubbery tumoral tissue with a



(a)



(b)

Fig. 1. T2-weighted transverse image (a) shows the infiltrative mass lesion extending between first and second phalanges. On contrast enhanced fat suppressed image (b), the lesion demonstrates heterogeneous high signal intensity and low signal areas corresponding to fat tissues.

similar cut surface. Microscopically, the tumor was composed of alternating streaks of mature adipose tissue traversed by the fibrous septa involved by spindle cells (Fig. 2). There was neither high mitotic activity nor cytological atypia. Fibrous septa were seen to entrap the nerve plexus and vascular structures. Minute collections of small vacuolated cells near the interface between the fibrous septa and the streaks of adipocytes were seen. The lesion was poorly marginated extending through the surgical margins. Based on the histopathologic features, the tumor was diagnosed as lipofibromatosis and the surgery was incomplete.




Fig. 2. Abundant adipose tissue traversed by fascicles of fibroblastic elements. Vessel involvement is present in the bottom left (hematoxylin and eosin X20).

After eight months, the child was presented with recurrence and referred to a Pediatric Oncology Unit for further management. She underwent local excision to alleviate discomfort and dysfunction. Histological diagnosis was lipofibromatosis with similar histological appearance as seen in the original tumor. The surgery was again incomplete. Since the last operation, she has been followed for three months with no evidence of recurrence.

Discussion

Lipofibromatosis is a rare benign soft tissue neoplasm of childhood, previously designated as infantile fibromatosis of non-desmoid type^{2,6}. Although Fetsch et al.¹ suggested that this tumor was likely a part of the spectrum of infantile fibromatosis, with its clinical and distinctive histopathologic features,

they proposed to classify it separately as "lipofibromatosis". These tumors had been variously diagnosed as a type of infantile fibromatosis, a variant of fibrous hamartoma of infancy and a fibrosing lipoblastoma¹. Lipofibromatosis has been described from infancy to the early second decade and in some cases has been congenital. The median age for the first surgery is one year. There is a male predominance with a male to female ratio of 2:1. It is most commonly seen in hands and feet and is slightly less common in thigh, trunk and head⁶. The etiology remains unknown².

The lesion usually measures 1 to 3 cm, with a median size of 2 cm, and is presented with a poorly circumscribed mass involving the subcutis and/or deep soft tissues. It is rare for lipofibromatosis to be over 5 cm in diameter⁶.

Histologically, mature adipose tissue accounts for the significant portion of the tumor³. The spindle fibroblast-like cells involve the septa of the abundant fat tissue. They appear bland and may have a rather primitive fibroblastic appearance; therefore, the lesion may resemble fibrous hamartoma of infancy. However, there are no primitive oval cells with myxoid stroma. Mitotic rate is low and there is usually no cellular atypia^{1,6}. Lipofibromatosis generally does not cause extensive fat effacement and does not demonstrate solid, sheet-like fibrous growth, which is common with fibromatosis. The corded arrangement of small epithelioid fibroblasts and lack of adipocytic component in calcifying aponeurotic fibroma are also important in differential diagnosis¹.

Entrapment of vessels, nerves and muscle is not uncommon². Diagnosis can be made easily with distinctive histopathologic features without an indication of immunohistochemistry^{1,2}.

On MR imaging, the detection of fat within this tumor may be a valuable distinguishing feature between lipofibromatosis and the other soft tissue fibrous tumors that occur in children³. In our case, the fatty elements clearly seen on T2-weighted images and fat saturation sequences helped in the differential diagnosis of these lesions.

In the review study of 45 patients with lipofibromatosis, the patients' ages ranged between 11 days to 12 years (median 1 year) at the time of the initial surgery, and among

patients who had recurrence, the shortest interval to development of the first clinical recurrence was two months and the longest was seven years. All patients except one had painless slowly growing lesion¹. The clinical features of the lesion in our patient were consistent with those described in the literature. The lesion with extensive infiltration of the surrounding tissue occurred at 15 months of age and grew gradually over nine months. Despite the surgery, it recurred after eight months.

The tumor has a high rate of local recurrence. However, neither metastases nor spontaneous regression has been reported with this entity^{2,3}. Congenital onset, male gender, incomplete excision and higher mitosis appear to be risk factors for recurrence. Complete surgical resection is the mainstay of treatment because of high predilection for recurrence in incompletely excised lesions^{1,6}. Likewise, the lesion with infiltrative borders in our case recurred after incomplete resection. Since most lesions have infiltrating borders, complete removal of the tumor might cause functional compromise. However, there are some cases with long-term follow-up who experienced no recurrence even though the lesion was incompletely excised^{1,3}. In the view of these circumstances, due to the paucity of literature that accurately predicts

safe conclusions regarding patient prognosis, management must be individualized based on the patient's condition.

In conclusion, although more documented cases of this entity have been published, insufficient clinical experience in treatment still remains. Nevertheless, the rareness of its presentation should be taken into account by the pathologist and considerable surgical judgment is of great importance.

REFERENCES

1. Fetsch JF, Miettinen M, Laskin WB, Michal M, Enzinger FM. A clinicopathologic study of 45 pediatric soft tissue tumors with an admixture of adipose tissue and fibroblastic elements, and a proposal for classification as lipofibromatosis. *Am J Surg Pathol* 2000; 24: 1491-1500.
2. Herrmann BW, Dehner LP, Forsen JW Jr. Lipofibromatosis presenting as a pediatric neck mass. *Int J Pediatr Otorhinolaryngol* 2004; 68: 1545-1549.
3. Teo HE, Peh WC, Chan MY, Walford N. Infantile lipofibromatosis of the upper limb. *Skeletal Radiol* 2005; 34: 799-802.
4. Nagarajan G, Deshpande A, Supe A. Progressive macrosyndactyly due to nerve territory-oriented lipofibromatosis: a case report. *Surgery* 2002; 131: 468-469.
5. Sasaki D, Hatori M, Hosaka M, Watanabe M, Kokubun S. Lipofibromatosis arising in a pediatric forearm--a case report. *Ups J Med Sci* 2005; 110: 259-266.
6. Miettinen M, Fetsch FC. Lipofibromatosis. In: Fletcher CD, Unni KK, Mertens F (eds). *World Health Organization Classification of Tumors: Pathology and Genetics, Tumors of Soft Tissue and Bone*. Lyon: IARC Press; 2005: 85.