

## Acute hemorrhagic edema of infancy: a case report

Burçe Can<sup>1</sup>, Mukaddes Kavala<sup>1</sup>, Zafer Türkoğlu<sup>1</sup>, Ebru Zemheri<sup>2</sup>

Departments of <sup>1</sup>Dermatology, and <sup>2</sup>Pathology, Social Security Göztepe Training Hospital, İstanbul, Turkey

**SUMMARY:** Can B, Kavala M, Türkoğlu Z, Zemheri E. Acute hemorrhagic edema of infancy: a case report. Turk J Pediatr 2006; 48: 266-268.

Acute hemorrhagic edema of infancy is a cutaneous leukocytoclastic vasculitis, clinically characterized by the acute development of peripheral edema and targetoid purpuric lesions on the face and extremities. The clinical picture has a violent onset with a short benign course followed by spontaneous complete recovery. We describe a five-month-old boy with acute hemorrhagic edema, in whom the disease appeared after antibiotic treatment for a cellulitis in front of the tragus.

*Key words:* acute hemorrhagic edema of infancy, vasculitis.

Acute hemorrhagic edema in infancy (AHEI) of the skin is a benign cutaneous leukocytoclastic vasculitis of infancy<sup>1</sup>. It usually affects children younger than two years of age. AHEI is characterized by fever, acral edema, and rosette-shaped purpuric plaques that show leukocytoclastic vasculitis of small dermal vessels on histologic examination<sup>2</sup>. AHEI has common clinical features with Henoch-Schönlein purpura (HSP), and is considered by some authors to be a variant of this syndrome<sup>3</sup>; others regard it as a distinct clinical entity<sup>2,4</sup>. Herein, we present a child with AHEI in whom the cutaneous eruption appeared after antibiotic treatment for a cellulitis in front of the tragus.

### Case Report

A five-month-old boy presented with symmetrical, erythematous, and edematous purpuric plaques on the face, buttocks, and distal part of the limbs. His history revealed that he had a fever and edema on the right ear. He had been taking ceftriaxone (1 g) for about five days for the cellulitis in front of the tragus. The cutaneous eruption appeared two days after treatment and the drug was discontinued.

His medical history revealed postnatal icterus of one month duration that improved without treatment. In the family history, his mother had developmental dysplasia of the hip, and his father had Behçet disease. He had a 2.5-

year-old healthy brother. He was still being fed with his mother's milk. There was no pathological finding on systemic examination. His temperature was 38.5°C.

On dermatologic examination, there were symmetrical, erythematous, and edematous purpuric plaques on the face, buttocks, and distal part of the limbs (Figs. 1, 2). Mucosal sites were spared.

Laboratory findings revealed a white blood cell count of 12,500/mm<sup>3</sup>. C-reactive protein (CRP) was 2.55 mg/dl (normal values <0.8 mg/dl). Other blood chemistry profiles and urinalysis were within normal range, and there was no blood in the feces. Chest X-ray showed normal findings. Further laboratory examinations, including pharyngeal exudate cultures, anti-ASO titer, antinuclear antibody, immunoglobulins and complement were normal or negative. The antiviral antibodies, including hepatitis B and C, human immunodeficiency virus, and herpes simplex were negative.

Results of histologic examination of a plaque showed perivascular neutrophilic infiltration, eosinophilic fibrinoid change of vessel walls and nuclear debris in upper and mid dermis (Fig. 3). Direct immunofluorescence study results were negative.

Clinical, histological and biologic features of the patient were consistent with acute infantile hemorrhagic edema. The patient was treated with oral hydroxyzine, which resulted in rapid



Fig. 1: Confluent rosette-shaped purpuric plaques of the cheeks.

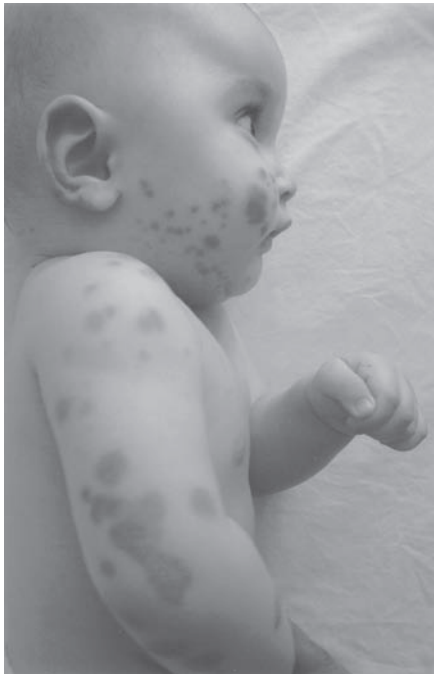

Fig. 2. Purpuric skin lesions on the right arm and face.

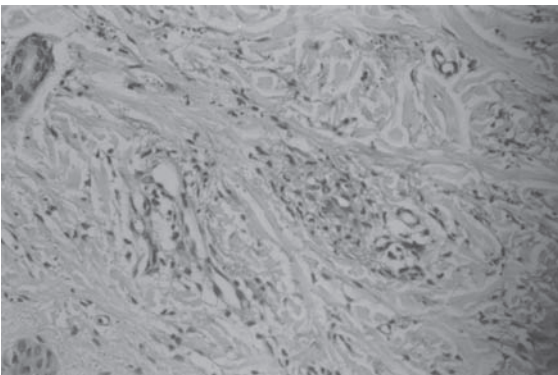


Fig. 3. Perivascular neutrophilic infiltrate, eosinophilic fibrinoid change of vessel walls and nuclear debris.

fading of the lesions and complete recovery within five days. Physical examination was normal at follow-up one month later.

### Discussion

Acute hemorrhagic edema of infancy is a variant of leukocytoclastic vasculitis that presents clinically as painful petechiae and ecchymoses that become edematous and develop a target-like appearance<sup>5</sup>. It was first described by Snow<sup>6</sup> in the United States in 1913. It is also known under the terms Finkelstein's disease and Seidlmayer's disease<sup>1</sup>. All patients have been infants and young children, with a majority younger than two years of age<sup>7</sup>.

Bacterial or viral infections, drugs, and less frequently, immunization, have been suggested to be the likely triggering mechanisms<sup>4</sup>. In our patient, both cellulitis in front of the tragus and antibiotic treatment with ceftriaxone preceded the appearance of AHEI by a few days.

First lesions appear on the skin in the form of urticarial plaques, hyperemia or small macules and papules. Within a few days these lesions grow in size and spread to 1-5 cm in diameter, and are round with sharp edges. They finally turn into homogeneous or dark-centered palpable non-pruritic hemorrhagic purpura<sup>8</sup>. Characteristically, the trunk is spared. The visceral involvement rarely dominates the clinical picture. In our patient as well, no systemic involvement was seen.

The typical histological appearance of the skin lesions in AHEI is leukocytoclastic vasculitis<sup>7</sup> presenting as a perivascular infiltrate of polymorphonuclear cells and lymphocytes with nuclear debris. Immunohistochemical studies demonstrated deposits of immune complexes and complement in and around vessel walls in some but not all cases<sup>5</sup>. Our patient's histopathology was consistent with leukocytoclastic vasculitis, and direct immunofluorescence was negative.

Acute hemorrhagic edema of infancy should especially be distinguished from HSP, acute febrile neutrophilic dermatosis, meningococemia, septicemia, purpura fulminans, child abuse, Kawasaki disease, and other diseases leading to cockade eruptions, such as erythema multiforme and urticaria<sup>5,7,8</sup>.

Some authors have speculated that hemorrhagic edema and HSP are separate entities, whereas others believe that they are different expressions of the same disorder and that the unifying factor is a hypersensitivity vasculitis<sup>5</sup>.

The differences between AHEI and HSP begin with the age of the patients: typically, the former affects children aged 4 months to 2 years, and the latter affects children aged 3 to 6 years. In contrast to AHEI, the skin lesions of HSP are more polymorphic and the fluorescence staining pattern of HSP mainly contains IgA, C3 and fibrin. AHEI classic features do not include symptoms such as vomiting, abdominal pain or renal alterations like in HSP<sup>4</sup>.

There is no specific treatment for AHEI. Antibiotics should be given when there is evidence of concurrent infection. Systemic corticosteroids and antihistamines do not seem to improve the course of the disease<sup>1</sup>. Although antihistaminic was given to our patient, we are not convinced that this treatment influenced the outcome of the disease.

The prognosis of the disease is usually benign and the evolution is self-limited, lasting from one to three weeks<sup>4</sup>.

We believe that this relatively unrecognized entity must be kept in mind by pediatricians

and dermatologists to make an early diagnosis and thereby avoid unnecessary treatment and concern.

#### REFERENCES

1. Taieb A, Legrain V. Acute haemorrhagic oedema of the skin in infancy. In: Textbook of Pediatric Dermatology (2<sup>nd</sup> ed). United Kingdom: Blackwell Science; 2002: 1569-1573.
2. Paradisi M, Annessi G, Corrado A. Infantile acute hemorrhagic edema of the skin. *Cutis* 2001; 68: 127-129.
3. Amitai Y, Gillis D, Wasserman D, Kochman RH. Henoch-Schonlein purpura in infants. *Pediatrics* 1993; 92: 865-867.
4. Manzoni AP, Vecili JB, Andrade CB, Kruse RL, Bakos L, Cestari TF. Acute hemorrhagic edema of infancy: a case report. *Int J Dermatol* 2004; 43: 48-51.
5. Dubin BA, Bronson DM, Eng AM. Acute hemorrhagic edema of childhood: an unusual variant of leukocytoclastic vasculitis. *J Am Acad Dermatol* 1990; 23: 347-350.
6. Snow IM. Purpura, urticaria and angioneurotic edema of the hands and feet in a nursing baby. *JAMA* 1913; 61: 217-255.
7. Saraçlar Y, Tinaztepe K, Adalıoğlu G, Tuncer A. Acute hemorrhagic oedema of infancy (AHEI) - a variant of Henoch-Schönlein purpura or a distinct clinical entity?. *J Allergy Clin Immunol* 1990; 86: 473-483.
8. Tomaç N, Saraçlar Y, Türkteş I, Kalaycı Ö. Acute hemorrhagic oedema of infancy: a case report. *Clin Exp Dermatol* 1996; 21: 217-219.