

## Fire-eater's pneumonia after aspiration of liquid paraffin

Özgür Karacan, İnsu Yılmaz, Füsün Öner Eyüboğlu

Department of Pulmonary Diseases, Başkent University Faculty of Medicine, Ankara, Turkey

**SUMMARY:** Karacan Ö, Yılmaz İ, Öner-Eyüboğlu F. Fire-eater's pneumonia after aspiration of liquid paraffin. Turk J Pediatr 2006; 85-88.

Fire-eater's pneumonia is a distinct type of chemical pneumonitis that results from aspiration of different types of hydrocarbons. This article describes a case of fire-eater's pneumonia due to accidental aspiration of liquid paraffin. The adolescent patient became febrile the day after the accident. The diagnosis of fire-eater's pneumonia was delayed because aspiration history was not divulged by the patient from the beginning. The most prominent chest X-ray finding was multiple pneumatoceles. He responded well to antibiotics and corticosteroids. Two months after the accident, the lesions had almost completely resolved and only minor scarring was evident. Diagnosis of fire-eater's pneumonia can be difficult, especially if key aspects of related history are not divulged by the patient. Corticosteroid therapy was thought to be beneficial in the rapid recovery of the present case together with broad spectrum antibiotics.

**Key words:** fire-eater's, pneumonia, aspiration, hydrocarbons, paraffin.

Acute pneumonitis after aspiration of hydrocarbons is most often seen in cases of accidental poisoning in children. Entertainers known as "fire eaters" are at risk for liquid hydrocarbon (LH) aspiration, and the distinct type of chemical pneumonitis that results from aspiration during the flame-blowing part of the show is called "fire-eater's pneumonia". In this report, we discuss the clinical manifestations, diagnostic work-up, and therapeutic approaches that were used in one adolescent who accidentally ingested liquid paraffin.

### Case Report

The patient was a 16-year-old male non-smoker. He had been healthy prior to the incident, and had been working as a waiter at a tourist hotel for two years. In August 2003, motivated by friends and the entertainment team at the hotel, the patient tried fire eating for the first time. During this attempt, he accidentally aspirated a mouthful of ignition fluid (lamp oil) that contained paraffin. Within hours he developed fever, nausea, vomiting, cough and retrosternal pain, but he refused to go to a hospital. The nausea and vomiting disappeared in two days, but the fever began to rise. Four days after the accident, the patient visited the emergency department of a health center. His

physical examination and chest X-ray findings were interpreted as pneumonia, and he was started on intramuscular ceftriaxone 2 g/d. This was administered for three days, but was discontinued because of persistent fever, chills and development of eyelid edema. He visited another hospital, where a chest X-ray was done and intravenous (i.v.) penicillin treatment was started. The radiograph showed multiple cavitory lesions in his lungs, and he was referred to our center for further diagnostic work-up.

The patient arrived at our hospital eight days after the accident. At this stage, he was thin, coughing and appeared ill. Initially, he concealed the fact that he had aspirated lamp oil. Physical examination revealed body temperature 38°C, tachycardia, tachypnea, oxygen saturation 95%, and mild abdominal tenderness in the epigastric area. All other findings were normal. Laboratory analysis showed mild leukocytosis (11,000/mm<sup>3</sup>), elevated erythrocyte sedimentation rate (59 mm/hr), and elevated serum lactate dehydrogenase (230 U/L). A peripheral blood smear showed increased numbers of polymorphonuclear leukocytes (PMNs; 71% on the differential). Other laboratory parameters were normal. Another chest X-ray was taken, and this showed a 3.5 cm in diameter partially

opaque lesion in the right lung. The lesion had smooth margins, was located craniolaterally to the minor fissure, and appeared to contain air. Two other lesions were also identified in the right lung, one cranial and one caudolateral to the hilus. The margins of both these lesions were poorly delineated, and there was infiltrate in the surrounding parenchyma (Fig. 1).

The patient was hospitalized for further diagnostic work-up. Thoracic computerized tomography revealed two thick-walled cavitary lesions that were interpreted as pneumatoceles. One was located in the anterior portion of the upper lobe of the right lung and the other in the medial segment of the middle lobe. Both showed air-fluid levels. The third lesion was in the anterior portion of the lower lobe of the right lung, and was characterized as a nodular lesion with surrounding infiltration. The tomography findings are shown in Figure 2.

We planned to rule out pulmonary tuberculosis by examining a sputum smear for acid-fast bacilli, but the patient was unable to provide a sputum sample. Fluid specimens from two gastric lavage and two bronchoalveolar lavage

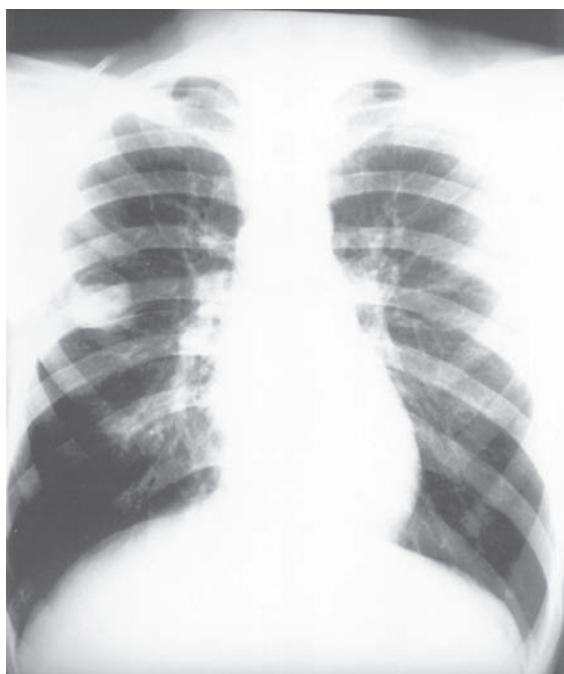

Fig. 1. A chest X-ray taken eight days after the accident shows a 3.5 cm-diameter partially opaque lesion in the right lung. Two other lesions were identified in the right lung: one cranial and the other caudolateral to the hilus, and both featuring infiltration in the surrounding parenchyma.

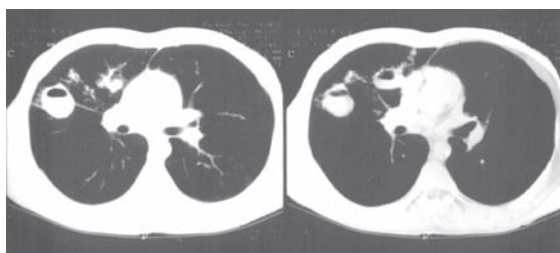


Fig. 2. Thoracic computerized tomography at the time of admission showed two pneumatoceles, one in the anterior portion of the upper lobe of the right lung and the other in the medial segment of the middle lobe. Both showed air-fluid levels. The third lesion was located in the anterior portion of the lower lobe of the right lung, and was characterized as a nodular lesion that contained air and had surrounding infiltration.

(BAL) procedures were negative for acid-fast bacilli. PPD were negative. Serological tests for C-AnCA and markers of connective tissue disorders were also negative. Wright's staining of a BAL fluid sample showed increased PMNs (90%), but no bacteria were detected. The BAL fluid was also cultured to assess for common bacterial pathogens, but no growth resulted. The results of pulmonary function testing, including measurement of carbon monoxide diffusion capacity, were normal. In light of the patient's high fever, increased erythrocyte sedimentation rate, and the high numbers of PMNs despite no bacterial pathogens in the BAL fluid, empirical antibiotic treatment was initiated. The regimen was i.v. sulbactam-ampicillin four times daily (total dose 4.5 g/d) and i.v. ciprofloxacin twice daily (total dose 400 mg/d). On the second day of this therapy, the patient related his unsuccessful experience of fire-eating which resulted in aspiration of lamp oil. We immediately added i.v. prednisolone (1 mg/kg/d) to the drug regimen and planned upper gastrointestinal endoscopy to investigate for any intestinal complications of LH ingestion. On endoscopy, hyperemic mucosa and a healing ulcer were detected in the antrum. Examination of a biopsy of antral mucosa revealed a peptic ulcer, and omeprazole was added to the treatment. On the third day of hospitalization, the patient's temperature normalized. After one week of i.v. antibiotics and prednisolone in hospital, the patient was stable enough to be discharged. The steroid treatment was discontinued, and he was discharged with a prescription for twice-daily treatment with oral ciprofloxacin (1 g/d) and oral amoxicillin-clavulanic acid combination (2 g/d).

The patient was re-checked twice monthly. All antibiotics were stopped after six weeks of therapy. Over a period of two months, he gained approximately 10 kg. At the time of writing (4 months' post-discharge), the patient was well and had no complaints. A second thoracic computed tomography scan done two months after the first showed complete resolution of the cavity in the middle lobe and almost complete healing of the lesion in the upper lobe of the right lung, with only a small amount of scarring at the site where the latter cavity had been. The nodular lesion in the lower lobe of the right lung had completely resolved, and the infiltration in the same lobe had regressed (Fig. 3).

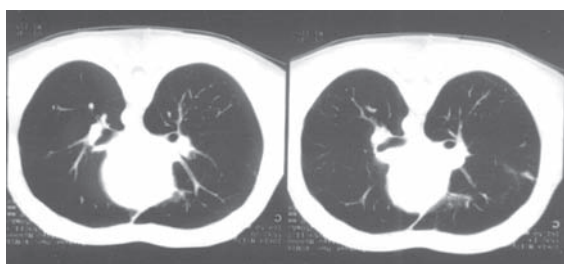


Fig. 3. Repeated thoracic computed tomography scan done two months after the first showed complete resolution of the cavity in the middle lobe and almost complete healing of the lesion in the upper lobe of the right lung, with only a small amount of scarring. The nodular lesion in the lower lobe of the right lung had completely resolved, and the infiltration in the same lobe had regressed.

## Discussion

Liquid hydrocarbons derived from petroleum are widely used in industry and in households. Humans may be exposed to these compounds in different ways. Accidental ingestion is most common in small children<sup>1</sup>, and most non-occupational cases are related to aspiration of medicines that contain liquid paraffin, like nose drops, throat gargles and purgatives<sup>2,3</sup>. Entertainer fire-eaters are obviously at risk for ingestion or aspiration of different kinds of LH. There are also reports of people using these chemicals for suicide<sup>4</sup>.

Lamp oils are aliphatic hydrocarbons that are mainly composed of N-paraffin. Paraffin oil is reported to be a major cause of accidental child poisoning in the United Kingdom, as its smell and color are appealing<sup>5</sup>. A literature review by Gentina et al.<sup>6</sup> summarized six previously published cases of fire-eater's

pneumonia in which the causative agent was paraffin oil. These authors proposed that low-viscosity volatile LHs are more toxic than more viscous compounds. Haas et al.<sup>7</sup> made a similar conclusion in their series of three hydrocarbon aspiration-pneumonia cases. They stated that aspiration of low-viscosity LHs (e.g., kerosene) tends to cause acute infectious lung disease, whereas aspiration of high-viscosity LHs (e.g., paraffin oil) tends to cause pseudotumoral exogenous lipid pneumonias. Our patient presented with acute pneumopathy accompanied by fever and cough. To our knowledge, this is only the eighth reported case of fire-eater's pneumonia due to paraffin oil aspiration.

Patients with LH aspiration pneumonia may show a range of radiologic findings. In a series of exogenous lipid pneumonia cases due to paraffin oil aspiration reported by Gondouin et al.<sup>2</sup>, the most frequent radiologic findings were alveolar consolidation (51%), ground-glass opacities (39%), and alveolar nodules (23%). In our case, we observed well-defined cavitory nodules (pneumatoceles) and alveolar infiltration. Petroleum-induced formation of pneumatoceles in the lung is explained by the check-valve mechanism. Thickening of bronchiolar walls causes progressive air trapping and, ultimately, pneumatocele formation. These lesions can also develop through coalescence of necrotic bronchioles. A review by Bergeson et al.<sup>8</sup> noted that pneumatoceles that developed in pediatric patients after LH intake were radiologically detectable three to 15 days later, and that the majority of these lesions resolved almost completely with no residual pleural or parenchymal scarring. In our adolescent case, we detected multiple pneumatoceles on a chest X-ray taken eight days after the accident, and a computed tomography scan two months later confirmed almost complete resolution of all three lesions. Unlike the children in the above-mentioned review, our patient was symptomatic when the pneumatoceles were radiologically apparent.

The clinical presentation in our case was similar to that described in previous reports<sup>6,9</sup>. This case emphasizes the importance of thorough history taking. Initially, the patient did not reveal that he had aspirated LH. As a result, unnecessary laboratory investigations were done, considerable treatment time was lost,

and we assessed for vasculitis, tuberculosis, and other conditions that present with cavitary lesions on chest X-ray.

Prophylactic use of antibiotics is not recommended for prevention of hydrocarbon pneumonitis<sup>6</sup>. However, once signs of secondary infection appear after aspiration of LH, antibiotic therapy should be started. In the cases of delayed clinical improvement and presence of cavitary lesions with signs of secondary bacterial infection, antibiotic treatment could be continued for 4-6 weeks<sup>10</sup>. It is important that the selected drug combination covers anaerobes and common Gram-positive and -negative pathogens. Our patient was febrile and had other signs and symptoms of pulmonary bacterial infection, and both his clinical condition and radiological findings improved after antibiotic administration. Upon learning that the patient had ingested LH, we also added corticosteroids to the therapy, though the efficacy of steroid treatment in this condition is disputed<sup>6,11</sup>. In this particular case, we think that corticosteroid therapy was beneficial in the recovery because we know that before corticosteroid addition, the patient had been treated with broad spectrum antibiotics for one week at different hospitals but remained unresponsive to the therapy with persistent fever.

This case of fire-eater's pneumonia with multiple pneumatoceles is of interest because it demonstrates that this pathology can result from aspiration of high-viscosity hydrocarbons (paraffin oil), not only from low-viscosity volatile materials like gasoline. This young patient responded very well to antibiotic and corticosteroid therapy, and all three lesions had almost completely resolved by two months after

the accident. Diagnosis of fire-eater's pneumonia can be difficult, especially if key aspects of related history are not divulged by the patient.

#### REFERENCES

1. Eade NR, Taussig LM, Marks MI. Hydrocarbon pneumonitis. *Pediatrics* 1974; 54: 351-359.
2. Gondouin A, Manzoni P, Ranfaing E, et al. Exogenous lipid pneumonia: a retrospective multicentre study of 44 cases in France. *Eur Respir J* 1996; 9: 1463-1469.
3. Nekarda K, Heckers H. Mineral oil pneumonia caused by throat gargles containing lipid paraffin. *Laryngol Rhinol Otol* 1977; 56: 14-19.
4. Perings SM, Hennersdorf M, Koch JA, et al. Lipoid pneumonia following attempted suicide by intravenous injection of lamp oil. *Med Klin* 2001; 96: 685-688.
5. Mok Q, Fraser J. Severe lung injury following aspiration of scented lamp oil. *Int Care Med* 2001; 27: 614.
6. Gentina T, Leblond TI, Birolleau S, et al. Fire eater's lung: seventeen cases and review of the literature. *Medicine* 2001; 80: 291-297.
7. Haas C, Lebas FX, Le Jeune C, Lowenstein W, Durand H, Hugues FC. Pneumopathies caused by inhalation of hydrocarbons: apropos of 3 cases. *Ann Med Interne* 2000; 151: 438-447.
8. Bergeson PS, Hales SW, Lustgarten MD, Lipow HW. Pneumatoceles following hydrocarbon ingestion. Report of three cases and review of the literature. *Am J Dis Child* 1975; 129: 49-54.
9. Yokohori N, Taira M, Kameyama S, et al. Acute form of exogenous lipid pneumonia caused by inhalation of liquid paraffin in a fire-eater. *Nihon Kogyuki Gakkai Zasshi* 2002; 40: 588-593.
10. Finegold SM, Fishman JA. Empyema and lung abscess. In: Fishman AP (ed). *Pulmonary Diseases and Disorders*. New York: McGraw Hill; 1998: 2021-2033.
11. Marks MI, Chicoine L, Legeve G, Hilmann E. Adrenocorticosteroid treatment of hydrocarbon pneumonia in children: a cooperative study. *J Pediatr* 1972; 81: 366-369.