

## Testicular cavernous hemangioma presenting as an ipsilateral lesion in a child with multicystic dysplastic kidney

Ecmel Işık Kaygusuz<sup>1</sup>, Handan Çetiner<sup>1</sup>, Serdar Moraloğlu<sup>2</sup>, Oktav Bosnalı<sup>2</sup>, Ayşenur Celayir<sup>2</sup>

Departments of <sup>1</sup>Pathology, and <sup>2</sup>Pediatric Surgery, Zeynep Kamil Maternity and Children's Training and Research Hospital, Istanbul, Turkey. E-mail: [ecmeli@yahoo.com](mailto:ecmeli@yahoo.com)

Received: 20 January 2015, Revised: 24 February 2015, Accepted: 19 March 2015

**SUMMARY:** Kaygusuz EI, Çetiner H, Moraloğlu S, Bosnalı O, Celayir A. Testicular cavernous hemangioma presenting as an ipsilateral lesion in a child with multicystic dysplastic kidney. Turk J Pediatr 2015; 57: 632-634.

Childhood malignant testicle tumors are very rare. In the literature to date, it has been reported that there are only 24 cavernous hemangioma cases existing in English literature. In this study, we discuss a testicular mass case which was diagnosed as cavernous hemangioma.

The patient, who followed for left multicystic dysplastic kidney since his birth, was admitted to our clinic with complaints of left testicular mass and pain at 1-year of age. Histopathological investigation revealed cavernous hemangioma.

Even if it has its characteristic ultrasonographic findings, radiology is too far beyond to eliminate the malignancy, final diagnosis can only be made after orchiectomy.

**Key words:** testis, hemangioma, cavernous, pediatric.

Testicular hemangiomas are very rare entities, although many case reports describe them in the literature. To date, 64 cases of testicular hemangioma have been identified through an unrestricted Pub Med search of cases from 1944 to 2013. Most subtypes have been reported and have been described as cavernous<sup>1-4</sup> capillary<sup>5-8</sup>, histiocytoid (epithelioid)<sup>9,10</sup>, and papillary endothelial hyperplasia<sup>11</sup>. To our knowledge, only 24 cases of cavernous hemangioma of the testis have been reported in literature. Most cases of hemangioma of the testis have been reported to occur in infancy, childhood, and young adults<sup>12</sup>.

Hemangiomas have a similar sonographic and magnetic resonance imaging appearance with malignant tumors of the testis, especially seminoma. The pathologist and surgeon have to be aware of this entity as the prognosis of the neoplasm determines the method of surgery. Intraoperative frozen study may be helpful in the differential diagnosis.

We report a case with intra-parenchymatous cavernous-type hemangioma of the testis, and discuss the pathological features and differential diagnosis of this rare benign

testicular neoplasm.

### Case Report

The patient who has been followed for left multicystic dysplastic kidney since birth presented with a painful solid mass in the left testis. The patient had no history of trauma or infection. Patient was lost for follow-up, however he re-admitted to our pediatric surgery clinic at 3 years of age with persistent mass in left testicle. Medical and family histories were unremarkable. On physical examination, the left testicle was firm and nodular with palpation, and ultrasonography measurements were; right testicle 13.3x7 mm, left testicle 24.5x15.8 mm. The left testicular paranchyma was hypoechoic heterogenous and with rough granules. On Doppler ultrasonography, left testicle was 12x17x27 mm and there was a solid cystic lesion 12x13x22 mm in size which contained multiple milimetric cystic cavities. The lesion was found to be vascularized at the inferior. Spectral investigation revealed high resistance blood flow. The appearance was thought to be most likely a cystic teratoma. There was a lymph node 7x3 mm in size with

cortical hypertrophy, and its fatty hilum was found faded.

The serum levels of alfa-fetoprotein (AFP) and beta-human chorionic gonadotropin were normal. The patient underwent left orchiectomy with high ligation.

On pathology examination there was a well-circumscribed nodule 25 mm in diameter located in the parenchyma of the left orchiectomy specimen. The cross-section of the mass was seen to be reddish/blue. Microscopically, the diagnosis of a cavernous hemangioma, showing characteristic features of a vascular tumor with proliferation, large blood-filled spaces of variable thickness and separated by fibrous tissue (Fig. 1). Microscopic appearance demonstrate vascular channels lined by a single layer of endothelial cells. Tumor nodule was spreading in between the seminiferous tubules. Mitotic figures and pleomorphism were not seen in neoplastic cells. Neoplastic cells were positive with CD31 and Vimentin. Immunohistochemical reaction with Inhibin, AFP and Placental Acid Phosphatase was negative in the neoplastic cells.

## Discussion

Testicular hemangioma is a very rare neoplasm. Twenty-four cases with testicular cavernous hemangiomas have been reported. The benign vascular tumors of the testis and their clinicopathologic features in the literature are summarized in Table I. A cavernous type hemangioma was diagnosed histopathologically in our case.

Average age of the patients with cavernous hemangioma was 37 years (median was 31, range from 3 months to 80 years) in the literature. Our case was one year old at admission.

Testicular hemangiomas commonly present with a palpable mass and pain. Our patient was admitted with a tender mass on left testis. The data from the literature indicate that roughly 70% of hemangiomas are left sided<sup>13</sup>.

The commonly reported ultrasonographic description of testicular hemangioma was that of a homogeneous hypoechoic mass hypervascular on Doppler studies which are similar to germ cell tumors<sup>2-8,12,14,15</sup>. Occasional ultrasonographic presentations as

a heterogeneous mass have been reported<sup>16,17</sup>. Ultrasonography revealed a 27 mm hypoechoic and heterogeneous mass in the testis in our case. Doppler sonography showed multiple cystic spaces and solid regions and demonstrated high vascular flow. Spectral Doppler traces were obtained in five random sites in the mass and resistive indexes.

In a study describing magnetic resonance imaging there were findings of testicular capillary hemangioma. However the findings were considered nonspecific, and a preoperative diagnosis of seminoma was rendered<sup>6</sup>.

All of the reviewed patients had undergone an orchiectomy except for two cases; one 18-year-old boy underwent a partial testicular resection for esthetic reasons, the other one, a 2-month-old boy, underwent an excisional biopsy which cured the neoplasm<sup>18</sup>. Although incomplete excision of testicular hemangiomas can result in local recurrence, no cases of malignant transformation have ever been reported<sup>19</sup>. Ideally, if a benign lesion is suspected, this can be confirmed by frozen section whereby enucleation can optimize testicular preservation.

Pathologically, information on the size of the tumors was on average 25 mm (range from 15 to 40 mm) in the literature, similar to our case. The macroscopic appearance of the reported hemangiomas is compatible with their vascular nature, described as reddish/brown, hemorrhagic, and tan/red or dark/red<sup>3-5,8,10,12,17</sup>. Macroscopic examination of the orchidectomy specimen revealed a solitary intratesticular hemorrhagic nodule. The microscopic appearance of cavernous

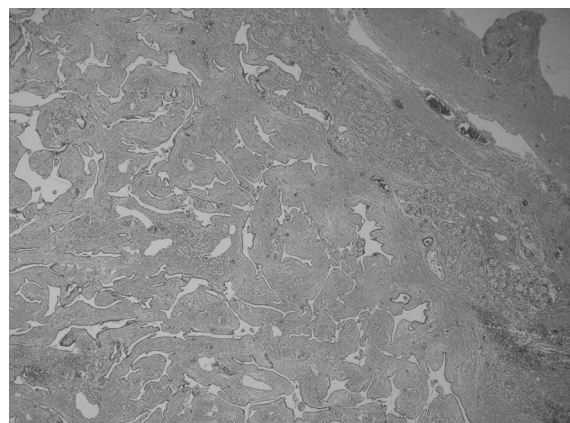


Fig. 1. Composed of large vessels with dilated lumina and thin walls in testicular hemangioma (H&E stain, X100).

hemangioma on H-E stain is characteristic. Rosai and co-workers<sup>20</sup> have used the vascular neoplasm concept for all histological types of hemangioma. Cavernous hemangiomas do not pose major difficulties in the histologic diagnosis. The differential diagnosis must include germ cell tumors, adenomatoid tumor, and sex-cord stromal tumors such as Sertoli cell tumor. The presence of proliferative cavernous type vascular spaces containing red blood cells are the most important microscopic evidence for differential diagnosis of cavernous hemangioma. Nuclear pleomorphism and mitotic activity are absent, and the cells lining vascular spaces are positive CD31, and negative for Inhibin.

To date, all reported vascular testicular tumors have demonstrated benign behaviour, with no evidence of focal recurrence or metastasis. However hemangioma can be very similar to malignant testicular tumors on clinical presentation and also by sonography.

In conclusion: cavernous hemangioma is the rarest tumor of the testicle, in either childhood or adult period. Even if it has its characteristic ultrasonographic findings, radiology is too far beyond to eliminate the malignancy, and final diagnosis can only be made by histopathologically. In testicle mass cases with negative tumor markers and hypo-echogenic central part with hyper-echogenic periphery by ultrasonography, cavernous hemangioma should be kept in mind.

#### REFERENCES

1. Fossum BD, Woods JC, Blight EM Jr. Cavernous hemangioma of testis causing acute testicular infarction. *Urology* 1981; 18: 277-278.
2. Hadzi-Djokic J, Pejic T, Acimovic M, Andrejevic V. The case of cavernous testicular hemangioma. *Acta Chir Iugosl* 2010; 57: 107-109.
3. Takaoka E, Yamaguchi K, Tominaga T. Cavernous hemangioma of the testis: a case report and review of the literature. *Hinyokika Kyo* 2007; 53: 405-407.
4. Venkatanarasimha N, McCormick F, Freeman SJ. Cavernous hemangioma of the testis. *J Ultrasound Med* 2010; 29: 859-860.
5. Bonetti LR, Schirosi L, Sartori G, et al. Rapidly-growing hemangioma of the testicle clinically simulating an aggressive neoplasm. A case report. *Pathologica* 2009; 101: 123-125.
6. Essig M, Knopp MV, Hawighorst H, et al. MRI of capillary hemangioma of the testis. *J Comput Assist Tomogr* 1997; 21: 402-404.
7. Mazal PR, Kratzik C, Kain R, et al. Capillary haemangioma of the testis. *J Clin Pathol.* 2000; 53: 641-642.
8. Mungan S, Turgutalp H, Ersoz S, et al. A rare neoplasm of the testis: capillary hemangioma. *Turk Patoloji Derg* 2011; 27: 80-83.
9. Banks ER, Mills SE. Histiocytoid (epithelioid) hemangioma of the testis. the so-called vascular variant of "adenomatoid tumor". *Am J Surg Pathol* 1990; 14: 584-589.
10. Mazzella FM, Sieber Sc, Lopez V. Histiocytoid hemangioma of the testis: a case report. *J Urol* 1995; 153(pt 1): 743-744.
11. Cricco CF Jr, Buck AS. Hemangioendothelioma of the testis: second reported case. *J Urol* 1980; 123: 131-132.
12. Suriawinata A, Talerman A, Vapnek JM, et al. Hemangioma of the testis: report of unusual occurrences of cavernous hemangioma in a fetus and capillary hemangioma in an older man. *Ann Diagn Pathol* 2001; 5: 80-83.
13. Kryvenko ON, Epstein JI. Testicular Hemangioma, A series of 8 Cases. *Am J Surg Pathol* 2013; 37: 860-866.
14. Tallen G, Hernaiz Driever P, Degenhardt P, et al. High reliability of scrotal ultrasonography in the management of childhood primary testicular neoplasm. *Klin Padiatr* 2011; 223: 131-137.
15. Talmon GA, Stanley SM, Lager DJ. Capillary hemangioma of the testis. *Int J Surg Pathol* 2011 ;19: 398-400.
16. Frank Rg, Lowry P, Ongcapin EH. Images in clinical urology. Venous cavernous hemangioma of the testis. *Urology* 1998; 52: 709-710.
17. Ricci Z, Koenigsberg M, Whitley K. Sonography of an arterio-venous-type hemangioma of the testis. *AJR Am J Roentgenol* 2000; 174: 1581-1582.
18. Mac Lennan GT, Quinonez GE, Cooley M. Testicular Juvenile capillary hemangioma: conservative management with frozen-section examination. A case report. *Can J Surg* 1994; 37: 493-496.
19. Nistal M, Garcia-Cardoso JV, Paniagua R. Testicular juvenile capillary hemangioma. *J Urol* 1996; 156: 1771.
20. Rosai J, Gold J, Landy R. The histiocytoid hemangiomas. A unifying concept embracing several previously described entities of the skin, soft tissue, large vessels, bone and heart. *Hum Pathol* 1979; 10: 707-730.