

## Rare vascular pathology sinus pericranii; becomes symptomatic with pseudotumor cerebri

Serhat Güler<sup>1</sup>, Burak Tatlı<sup>2</sup>

Divisions of Pediatric Neurology, Department of Pediatrics, <sup>1</sup>Bezmialem University Faculty of Medicine, and <sup>2</sup>Istanbul University İstanbul Faculty Medicine, İstanbul, Turkey. E-mail: serhatguler@hotmail.com

Received: 14 January 2015, Accepted: 21 April 2015

**SUMMARY:** Güler S, Tatlı B. Rare vascular pathology sinus pericranii; becomes symptomatic with pseudotumor cerebri. Turk J Pediatr 2015; 57: 618-620.

Sinus pericranii (SP) is an uncommon vascular pathology that is characterized by a nodular structure emerging from the scalp. It is generally asymptomatic. Typically, it is close to soft, compressive, fluctuant swelling, intracranial sinus. The swelling increases during the Valsalva maneuver, jugular vein compression, coughing, or crying attacks. The diagnosis was confirmed by CT, MRI, and MR angiography. Here, we conclude that SP is a rare cause of headache and that the asymptomatic lesion become symptomatic as a result of association with pseudotumor cerebri.

**Key words:** sinus pericranii, pseudotumor cerebri, headache.

Sinus pericranii (SP) is a rare vascular pathology that results from abnormal communication between the intracranial and extracranial venous systems<sup>1</sup>. It most commonly occurs in the pediatric age group. In most instances, SP presents as a soft-tissue swelling on the scalp<sup>2</sup>. An elevation in intracranial pressure increases the size of the lesion. SP most commonly occurs midline in the frontal region. It is often asymptomatic. Treatment is usually for cosmetic purposes<sup>2,3</sup>. Here, we conclude that SP is a rare cause of headache and that the asymptomatic lesion becomes symptomatic as a result of association with pseudotumor cerebri (PC).

### Case Report

An eight-year-old male patient, with no prior complaints related to SP, consulted a pediatrician for a headache which began three weeks earlier, and for a painless swelling on his vertex that his mother noticed while giving him a bath. Patient guided ophthalmologist due to detecting normal cranial computed tomography (CT). Patient was diagnosed with papilledema that was detected in the eye examination and was applied to our clinic for further examination.

Upon physical examination, soft tissue that was

round, fluctuant, nonpulsatile, painless, and 3x2 cm in size was observed. The mother stressed that there were no such lesions in the medical history of patient. A bilateral papilledema was not detected in the fundus examination. The patient's weight and height fell in the 50–75 percentile, and secondary sex characters were not developed.

There was no significant feature or trauma in the patient's medical history. Routine biochemical values and complete blood count were normal. Cranial magnetic resonance imaging (MRI) and magnetic resonance venography (MR) demonstrated that there were ectatic venous vascular structures linked with the sagittal sinus, posteriorly on the vertex level in the right frontal region, and the patient was diagnosed with SP. A cranial MRI did not reveal any pathology that might have increased intracranial pressure and mass. The patient underwent a lumbar puncture because the flattened appearance of the transverse sinus revealed by the MRI venography was compatible with PC. The patient's cerebrospinal fluid pressure was 30 mm/Hg, and he was diagnosed with PC. Acetazolamide therapy was initiated. After 12 weeks of therapy, the papilledema disappeared. However, the swelling on the vertex persisted.

## Discussion

Sinus pericranii is an uncommon vascular pathology characterized by a nodular structure that emerges from the scalp and is the result of an abnormal connections between the extracranial and intracranial venous system. Patients are generally asymptomatic. Typically, it is a close to soft, compressive, fluctuant

swelling, intracranial sinus. The swelling increases during the Valsalva maneuver, jugular vein compression, coughing, or crying attacks<sup>4</sup>. SP most commonly occurs in the frontal region (40%). However, it can be seen on the parietal, temporal, occipital, and mastoid bones. Most of the lesions are in the median or paramedian region. Lateral localization is extremely rare<sup>5</sup>. In our case, it was observed in the frontal paramedian region, too.

Sinus pericranii etiology is not fully elucidated. It is divided into three types: congenital, spontaneous, and traumatic. After trauma and cranial injuries, rich vein circulation in the skin and intracranial cavity can cause SP. SP can spontaneously occur when there is erosion in the skull caused by increased intracranial pressure<sup>1,3</sup>. If SP is welded congenital, incidence of SP increases with other vascular pathologies such as venous angioma, aneurysmal malformations, internal cerebral vein, and cavernous hemangiomas. Thus, all cerebral vascular pathology should be considered in patients diagnosed with SP<sup>5</sup>. However, there have been no prior reports of

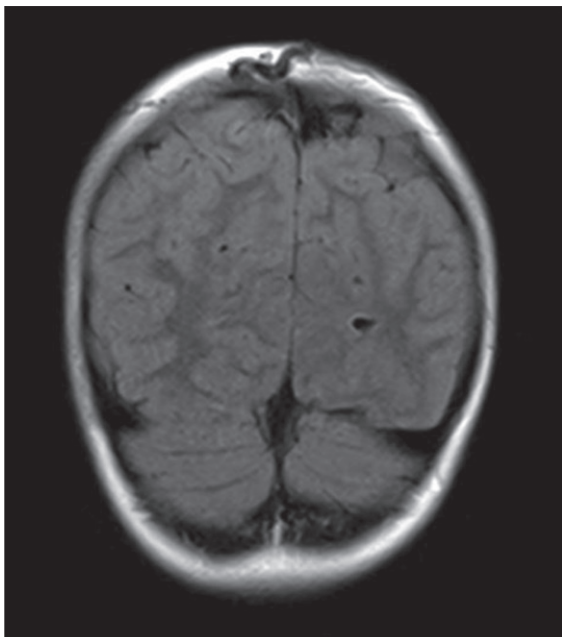


Fig. 1. In the right frontal region, at vertex level, ectasic venous vascular structure that links with sagittal sinus.

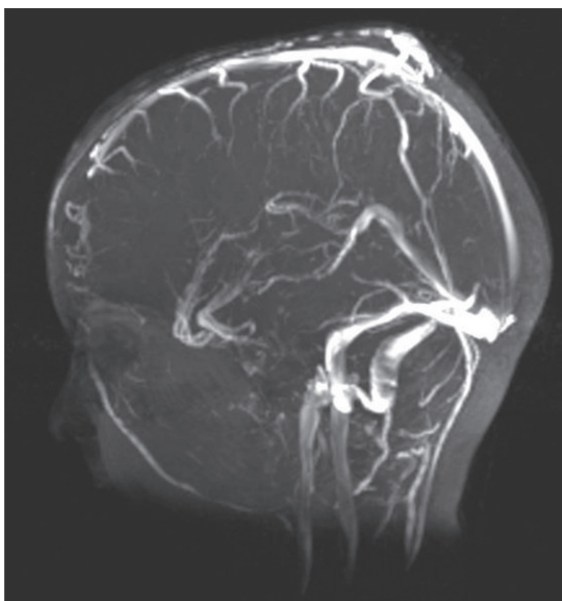


Fig. 2. Ectasic venous vascular structure that links with sagittal sinus (MR venography).

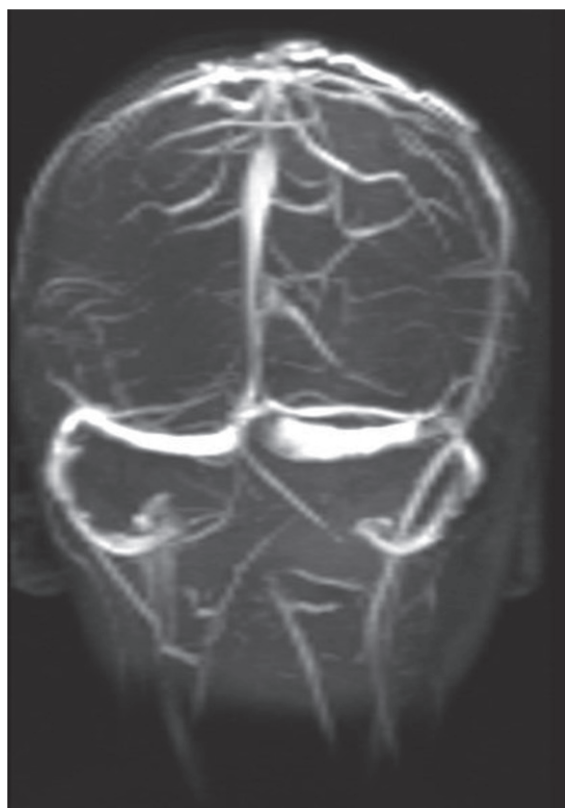

Fig. 3. The flattening on the left transverse sinus (pseudotumor cerebri).

PC with the SP. In our case, flattening in the transverse sinus was observed. This supports the diagnosis of PC, and this finding explains the headache. There were no pathological features other than that.

The family and the patient were not aware of the lesion until the age of eight. We believe they became aware of this symptom because of the addition of PC to the congenital anomalies. SP was thought to slightly decrease intracranial pressure in these patients. However, it is unknown whether this patient's lesion is caused by congenital or spontaneous SP that is secondary to increased intracranial pressure.

The diagnosis was confirmed by CT, MRI, and MR angiography. The MRI and CT indicated a transosseous connection<sup>4</sup>, which is essential to show the connection between intracranial dural venous sinuses and vascular mass<sup>5</sup>. However, this connection was not shown on the CT. Thus, MRI and MR angiography is essential for diagnosis and differential diagnosis of patients. In this case, vascular anomalies, anatomic variations, and developmental venous anomalies were not observed on the MRI and the MR angiography. Flattening in the transverse sinus that supports the existence of PC was observed in normal venous drainage.

Cranial MRIs were analyzed in terms of thrombosis, hydrocephalus, and intracranial mass screening to different a diagnosis of PC. All endocrine and biochemical tests were performed. Drug use was questioned and considered to be idiopathic. In the differential diagnosis of SP, cavernous hemangiomas, dural fistulas, meningoceles, meningoencephaloceles, lipoma, and other soft tissue tumors should be considered. Traumatic leptomenigeal cyst, arteriovenous fistulas, and subepicardial hydromas should be noted<sup>3,4</sup>. Hemorrhage, thrombosis, infection, and embolism are complications in SP. We presented the first case of SP associated with PC. Although the fundus examination was normal and headaches healing, a mass on the vertex continued to be observed.

Sinus pericranii has a great prognosis. There is a very low probability of traumatic and spontaneous hemorrhage. Surgery is not required unless the lesion causes cosmetic deformity and discomfort. Spontaneous regression has been observed in some cases<sup>7</sup>.

Some authors recommend treatment for air embolism and hemorrhaging that may occur as a result of trauma<sup>3</sup>. However, in our patient, all complaints decreased after PC therapy. Thus surgical treatment was not considered. Here, we present our experience in SP: an extremely rare vascular pathology presented with headache and was proven to associate with PC for the first time. We emphasize that the lesion caused the headache itself and definitely needs to be considered in terms of PC.

#### REFERENCES

1. Sakai K, Namba K, Meguro T, et al. Sinus pericranii associated with a cerebellar venous angioma--case report. *Neurol Med Chir (Tokyo)* 1997; 37: 464-467.
2. Bollar A, Allut AG, Prieto A, Gelabert M, Becerra E. Sinus pericranii: radiological and etiopathological considerations. Case report. *J Neurosurg* 1992; 77: 469-472.
3. Ota T, Waga S, Handa H, Nishimura S, Mitani T. Sinus pericranii. *J Neurosurg* 1975; 42: 704-712.
4. Bhutada S, Lokeshwar MR, Pandey A, Kulkarni M. Sinus Pericranii: a case report and review of literature. *Indian J Pediatr* 2012; 79: 1523-1525.
5. Luker GD, Siegel MJ. Sinus pericranii: sonographic findings. *AJR Am J Roentgenol* 1995; 165: 175-176.
6. Gandolfo C, Krings T, Alvarez H, et al. Sinus pericranii: diagnostic and therapeutic considerations in 15 patients. *Neuroradiology* 2007; 49: 505-514.
7. Brook AL, Gold MM, Farinhas JM, Goodrich JT, Bello JA. Endovascular transvenous embolization of sinus pericranii. Case report. *J Neurosurg Pediatr* 2009; 3: 220-224.