

Importance of neurologic and cutaneous signs in the diagnosis of Schimke immuno-osseous dysplasia

Ayşe İpek Polat¹, Uluç Yiş¹, Müge Ayanoğlu¹, Ayşe Semra Hız¹, Handan Güleriyüz², Tülay Öztürk-Atasoy², Cornelius F. Boerkoel³

¹Division of Pediatric Neurology, Department of Pediatrics, ²Division of Pediatric Radiology, Department of Radiology, Dokuz Eylül University Faculty of Medicine, İzmir, Turkey, ³Department of Medical Genetics, The University of British Columbia, Vancouver, Canada. E-mail: ulyis@yahoo.com

Received: 14 January 2015, Revised: 12 March 2015, Accepted: 27 July 2015

SUMMARY: Polat AI, Yiş U, Ayanoğlu M, Hız AS, Güleriyüz H, Öztürk-Atasoy T, Boerkoel CF. Importance of neurologic and cutaneous signs in the diagnosis of Schimke immuno-osseous dysplasia. Turk J Pediatr 2015; 57: 509-513.

Schimke immuno-osseous dysplasia is an autosomal recessive multisystem disorder caused by defects in SWI/SNF-related, matrix-associated, actin-dependent regulator of chromatin, subfamily a-like 1 gene (SMARCA1). SMARCA1 product is a helicase that has role in selective cellular proliferation. The disorder is characterized by spondyloepiphyseal dysplasia with short stature, nephropathy, T cell deficiency, neurologic and cutaneous signs. Patients may have hyperpigmented skin lesions similar to café au lait spots. Symptoms and disease severity in Schimke immuno-osseous dysplasia varies from patient to patient. Genetic, epigenetic and environmental factors play role on the severity of the disease. Here we report on a patient with short stature, steroid resistant nephrotic syndrome and recurrent infections. Cutaneous findings and developmental delay helped us to reach the diagnosis of Schimke immuno-osseous dysplasia. A homozygous missense mutation in SMARCA1 gene confirmed the clinical diagnosis.

Key words: Schimke immuno-osseous dysplasia, cutaneous signs, SMARCA1 gene.

Schimke immuno-osseous dysplasia (SIOD) is an autosomal recessive multisystem disorder characterized by spondyloepiphyseal dysplasia resulting in short stature, nephropathy and T-cell deficiency. Nearly all affected individuals have progressive steroid resistant nephropathy which terminates with end-stage renal disease. Opportunistic infections resulting from T-cell deficiency are common cause of death.¹ The spectrum of disease ranges from an infantile or early-onset form leading to death early in life to a juvenile or later-onset form with survival into adulthood.^{1,2} More than half of the patients have pigmented macules. Most of the patients have headaches, transient ischemic attacks and stroke due to premature atherosclerosis.³ Patients may have disproportionately large or small head, but imaging studies do not show structural abnormalities as a cause of abnormal head growth. About 15% of patients have social, language, motor, or cognitive abnormalities. There may also be subtle brain histological

abnormalities suggestive of perturbed migration of neuroglial cells such as heterotopia, irregular cortical thickness, incomplete gyral formation, and poor definition of cortical layers.⁴

Case Report

A three-year-old boy was consulted for the evaluation of psychomotor retardation. He had delayed fine motor skills and good social interaction. He had no history of seizures. He had numerous hospitalizations for infections including pneumonia, diarrhea, urinary tract and skin infections and had been treated for nephrotic syndrome since two years of age. He was born at 37th weeks of gestation as the second child of healthy consanguineous parents. His birth weight was 2400 g. There was not any sibling with the same complaints. At clinical examination he had disproportionately short stature (83 cm; <3rd percentile), low weight (12 kg; <3rd percentile), normal head

circumference (51cm; 75th-90th percentile). Abnormal physical examination findings included relative macrocephalic appearance, disproportionate short stature, a wide and depressed nasal bridge, broad nasal tip, short neck and trunk, protruding abdomen, and multiple hyperpigmented skin lesions resembling café au lait spots (Figs. 1,2). Hyperpigmented lesions size ranged between 0.2-1.5 cm and localized mostly on the trunk. There was no family history of neurofibromatosis, and there was no neurofibroma, axillary or groin freckling. He did not have any teeth abnormalities. Deep tendon reflexes were normal, there was no spasticity and cerebellar dysfunction. Eye examination showed corneal clouding. He was able to speak a few words and sit without support. Investigations for metabolic diseases including mucopolysaccharidosis and oligosaccharidoses, particularly nephrosialidosis were normal. Thyroid function tests showed subclinical hypothyroidism with elevated TSH and thyroid replacement treatment was started. At the administration white blood cell count was 6900/mm³ (Normal ranges: 4000-12000/mm³), lymphocyte count was 1300/mm³ (Normal ranges: 1500-3000/mm³) and neutrophil count was 4300/mm³ (Normal ranges: 3000-5800/mm³). Serum immunoglobulin G levels (290 mg/dl and 93mg/dl) were found markedly reduced (Normal ranges: 345-1236 mg/dl). The other immunoglobulin levels (Patient's Ig A level: 78 mg/dl, normal Ig A ranges: 14-159 mg/dl, Patient's Ig M level: 45 mg/dl, normal Ig M ranges: 43-207 mg/dl) were normal. Anti HBs was negative despite regular vaccination. Human intravenous immunoglobulin once a month and trimethoprim-sulfamethoxazole prophylaxis were initiated. Later in the course hematological tests revealed severe lymphopenia (white blood cell count 7000/ mm³ and lymphocyte count 900/ mm³). He had been diagnosed as nephrotic syndrome with permanent proteinuria, edema and hyperlipidemia. The patient did not improve with steroid and cyclosporine treatment. Hypertension was noted. Atorvastatin, losartan and enalapril maleate treatment was given. Renal biopsy showed fibrotic cortex, sclerotic glomeruli and thick arterial walls, compatible with end stage renal disease. The last BUN (blood urea nitrogen) was 33 mg/dl and creatinine was 4.01 mg/dl. Urine protein was 4.8 g/day. He

was under hemodialysis therapy. Bone survey revealed ovoid, flattened vertebral bodies, small deformed capital femoral epiphyses, dysplastic acetabulum, hip subluxation and J shaped sella (Figs. 3-5). Brain magnetic resonance imaging was normal. Multiple hyperpigmented skin lesions along with frequent infections, disproportionate short stature and nephrotic syndrome suggested Schimke immuno-osseous dysplasia. The clinical diagnosis was confirmed by the identification of the homozygous missense mutation c.2459G>A (p.R820H) in SMARCAL1. Parents were referred to Genetics Clinic for genetic counseling.

Discussion

Schimke immuno-osseous dysplasia (SIOD) is an autosomal recessive multisystem disorder with skeletal, renal, immune, vascular and hematopoietic involvement.¹ The disorder is caused by mutations SMARCAL1 which encodes Hep-A related protein (HARP).² SMARCAL1 is an ATP-dependent annealing helicase that takes role in selective cellular proliferation. Schimke immuno-osseous dysplasia is caused by a deficiency in this annealing helicase activity, which usually correlates with the disease severity.⁵ It is a spondyloepiphyseal dysplasia that usually leads to very short stature with abnormal body proportions. It is accompanied by steroid resistant and progressive nephropathy leading to end stage renal failure and cellular immune deficiency with prominent lymphopenia leading to recurrent infections. Hyperpigmented skin lesions, central nervous system involvement, thyroid and ocular abnormalities are other clinical features of the disease.¹ Patient was referred to our clinic with psychomotor retardation. After the recognition of cafe au lait like lesions, diagnosis of SIOD was considered in our case who had been followed up with recurrent infections, steroid resistant nephropathy, hypothyroidism and growth retardation. This case gave us the chance to emphasize the importance of full body examination in neurology clinics. One should consider SIOD in patients with typical cutaneous lesions and dysmorphic features who were referred to neurology clinics with psychomotor retardation.

Diagnosis of SIOD is primarily based on clinical features. Dysmorphic findings including low

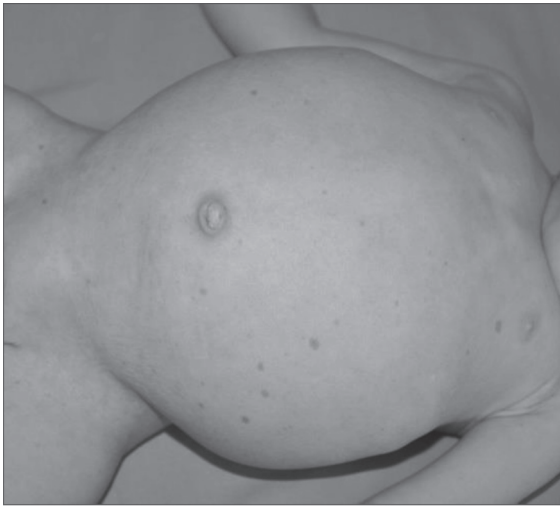

Fig. 1. Cafe au lait like hyperpigmented lesions and protruding abdomen

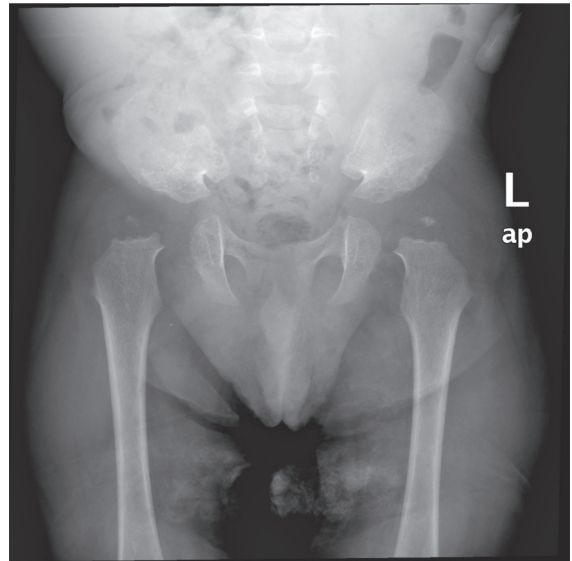


Fig. 3. Pelvic radiograph reveals small and displaced capital femoral epiphyses, dysplastic acetabulum and hip subluxation.

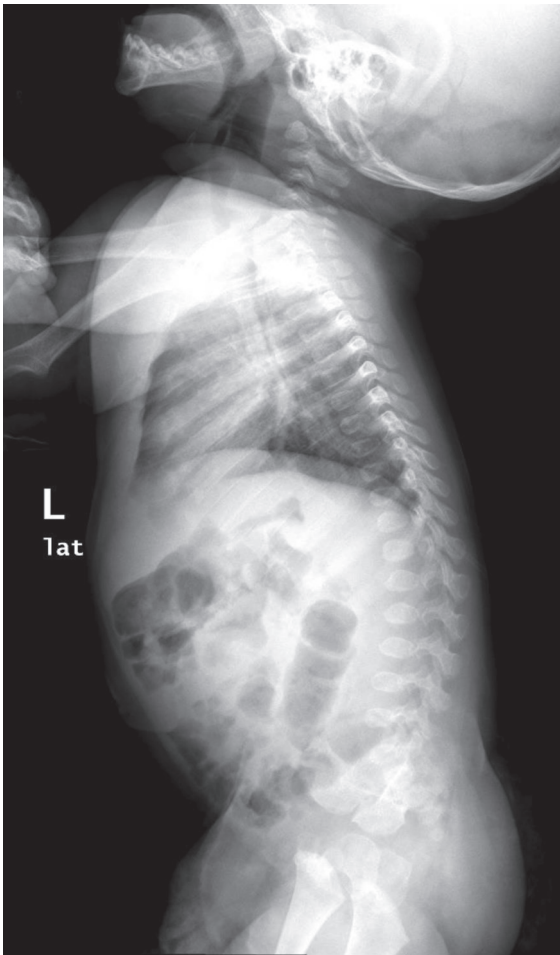


Fig. 2. Lateral dorsolumbar radiograph shows oval vertebral bodies with an anterior inferior beak.

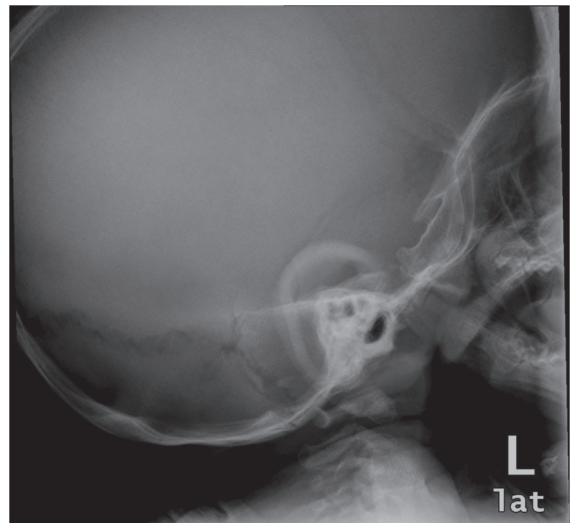


Fig. 4. On the lateral view of the skull J-shaped sella is seen.

nasal bridge, bulbous nasal tip, short stature with short neck and trunk, lumbar lordosis and protruding abdomen are typical features.¹ Affected individuals may have some ectodermal abnormalities including fine, sparse hair, microdontia or hypodontia and cafe au lait like hyperpigmented lesions and corneal opacities.³⁻⁷ Physical examination of our patient showed relative macrocephaly, wide and depressed nasal bridge, broad nasal tip, short neck and trunk, protruding abdomen with multiple hyperpigmented skin lesions resembling cafe au lait spots. It was showed that decreased

cellularity of the resting cartilage causing irregular nests of chondrocytes below the growth zone and abnormal bone formation cause chondro-osseous abnormalities.⁸ The most common skeletal abnormalities include ovoid and flattened vertebral bodies, broad thorax, hip subluxation, hypoplastic/dysplastic acetabulum, small and displaced capital femoral epiphyses. Radiological investigations of our patient revealed ovoid and malformed vertebral bodies and other skeletal abnormalities including displaced femoral capitis, hip subluxation and J-shaped sella turcica.

Almost all SIOD patients have proteinuria evolving into renal deficiency. Most commonly reported renal pathology is focal segmental glomerulosclerosis. After the diagnosis of growth retardation, nephropathy generally becomes evident in 5 years. The renal disease is refractory to treatment with corticosteroids, cyclosporine and cyclophosphamide. Renal transplantation can be considered.^{1,3} Our patient had been followed up with steroid resistant and cyclosporine unresponsive nephropathy since the age of 9 months. Renal biopsy of our patient was compatible with end stage renal disease and did not give any information about the etiology of renal pathology.

T cell deficiency is prominent with reduced CD4 and CD8 levels, with normal CD4/CD8 ratio and lymphopenia.^{1,3} Progressive hematological dysfunction can be seen with development of anemia, neutropenia or thrombocytopenia.¹ Because of T cell mediated immune deficiency, the patients have an increased risk of opportunistic infections and suffer from various infections caused by bacteria, viruses or fungi.³ Patients with severe disease usually die between 4-8 years of age. The most common cause of death is infections.^{1,3,8} Combined renal and bone marrow transplantation may provide some benefit.⁶ No response to cyclosporine treatment was recorded and due to rapid progression of steroid resistant nephrotic syndrome and severe recurrent infections, bone marrow transplantation could not be considered. If patients survive from severe infections, end stage renal deficiency develops and causes death by mean age of 8 years.^{1,3,8} Our patient suffered from severe infections and sepsis which caused long stay in intensive care unit and failure of extubation. The patient died at the age of 4

years because of recurrent infections.

Deguchi et al.⁴ suggested in their study that 15% of SIOD patients have social, language, motor or cognitive abnormalities. Neurodevelopmental delay was attributed to the chronicity of the disease or recurrent cerebral ischemic events. Nearly half of the SIOD patients have neurological findings, such as severe migraine-like headaches, transient ischemic attacks or strokes which are thought to be caused by progressive atherosclerosis.³ Our patient also had developmental delay especially in motor and language skills but cranial magnetic resonance imaging was normal. Developmental delay in our patient may be due to the neurological features of the primary disease or it may result from frequent hospitalizations due to infections and chronic renal disease.

Differential diagnosis of SIOD should be made in consideration with the syndromes associated with nephrotic syndrome including conorenal syndrome, Nail-patella syndrome, Braegger syndrome and syndromes associated with immune deficiency such as cartilage-hair syndrome, skeletal dysplasia with combined immune deficiency, short limb skeletal dysplasia with humoral immune deficiency, spondylo-mesomelic-dysplasia etc. The co-occurrence of T cell mediated immune deficiency, disproportionate short stature and steroid resistant, progressive nephropathy is unique to SIOD³.

Schimke immuno-osseous dysplasia was shown to be related to loss of function mutations in SMARCAL1.⁷ Disease severity is inversely proportional to residual SMARCAL1 activity.⁶ Elizendo et al.⁶ reported that R820H mutation which leads to the loss of ATP dependent helicase activity causes severe disease. The catastrophic course in our patient may also be related to the homozygous missense mutation c.2459G>A (p.R820H) in SMARCAL1.

In conclusion, cutaneous and neurologic findings are very important to reach the diagnosis in SIOD. Schimke immuno-osseous dysplasia should be considered in patients with short stature, steroid resistant nephrotic syndrome and immunodeficiency who have skin lesions resembling café au lait spots and psychomotor retardation.

REFERENCES

1. Boerkoel CF, O'Neill S, Andre JL, et al. Manifestations and treatment of *Schimke immuno-osseous dysplasia*: 14 new cases and a review of the literature. *Eur J Pediatr* 2000; 159: 1-7.
2. Yue Z, Xiong S, Sun L, et al. Novel compound mutations of *SMARCAL1* associated with severe *Schimke immuno-osseous dysplasia* in a Chinese patient. *Nephrol Dial Transplant* 2010; 25: 1697-1702.
3. Morimoto M, Baradaran-Heravi A, Lücke T, Boerkoel CF. *Schimke immuno-osseous dysplasia* 2002 (updated 2013). *GeneReviews* (Internet).
4. Deguchi K, Clewing JM, Elizondo LI, et al. Neurologic phenotype of *Schimke immuno-osseous dysplasia* and neurodevelopmental expression of *SMARCAL1*. *J Neuropathol Exp Neurol* 2008; 67: 565-577.
5. Yusufzai T, Kadonaga JT. HARP is an ATP-driven annealing helicase. *Science* 2008; 322: 748-750.
6. Elizondo LI, Cho KS, Zhang W, et al. *Schimke immuno-osseous dysplasia*: *SMARCAL1* loss of function and phenotypic correlation. *J Med Genet* 2009; 46: 49-59.
7. Clewing JM, Fryssira H, Goodman D, et al. *Schimke immunoosseous dysplasia*: suggestions of genetic diversity. *Human Mutat* 2007; 28: 273-283.
8. Saraiva JM, Dinis A, Resende C, et al. *Schimke immuno-osseous dysplasia*: case report and review of 25 patients. *J Med Genet* 1999; 36: 786-789.