

Neonate born to hepatitis B carrier mother presenting with congenital onychodysplasia of the index finger (Iso-Kikuchi syndrome)

Hiro Matsukura¹, Yoko Oose², Hiroyoshi Yuki²

Departments of ¹Pediatrics and ²Obstetrics and Gynecology, Saiseikai Toyama Hospital, Toyama, Japan

E-mail: matsukura-npr@umin.org

To The Editor,

Congenital onychodysplasia of the index fingers, also known as Iso-Kikuchi syndrome, is characterized using five diagnostic criteria: congenital occurrence, unilateral or bilateral involvement of the index fingers, variation in nail appearance, possible hereditary involvement and frequently associated bone abnormalities¹⁻⁵. Herein, we present the case of a newborn with congenital onychodysplasia of the left index finger.

A 2,480 g male neonate was born to a hepatitis B carrier mother at 38 weeks gestation by cesarean section. Hepatitis B immune globulin in combination with the recombinant hepatitis B vaccine was given at the time of birth. Two additional doses of the recombinant hepatitis B vaccine were scheduled over the first 6 months to prevent vertical transmission of hepatitis B virus (HBV). At birth, physical examination showed micronychia on the ulnar aspect of the left index finger (Fig. 1b). No limitation in clasping the left hand or spreading out the palm of the left hand was observed. A lateral X-ray showed a Y-shaped bifurcation of the distal phalanx of the left index finger (Fig. 1a). A diagnosis of congenital onychodysplasia of the index finger (COIF) was confirmed. No other family member had similar features. The parents were unrelated.

COIF is characterized by the full spectrum of nail dysplasia, including anonychia, micronychia and polyonychia (rudimentary splitting), hemionychocryptosis, irregular lunula and nail misalignment¹⁻⁵. Both sexes are affected equally, with international incidence of 4.2 cases per 100,000 live births⁵. COIF, which is usually congenital, can be transmitted in an autosomal or recessive dominant inheritance pattern,

although sporadic cases are described and are regarded as *de novo* mutations^{1,5}. Our newborn filled four of the five criteria, with no reported positive family history.

The exact pathogenesis remains unknown. In utero, ischemia of the palmar artery and a dysplastic change in the crescent-shaped cap of the distal phalanx have been proposed as the two main candidate pathogenetic mechanisms^{1-3,5}. Exposure to teratogens during pregnancy, especially to antidepressants, antiepileptics and abortifacient drugs, and to insulin have been described in the literature as causes⁵. The mother never took any medication that might have influenced the onset of COIF during pregnancy.

Skin and nail abnormalities are frequently associated with liver disease⁶. Although HBV-associated COIF has not yet been reported in the literature, HBV infection might cause COIF, because various nail abnormalities have been associated with HBV infection⁶. Transplacental transmission of HBV might occur, especially if mothers are positive for both hepatitis B surface antigen (HBsAg) and hepatitis B envelope antigen (HBeAg) and have high viral loads⁷. In our case, transplacental transmission was unlikely because of the HBeAg-negative HBsAg carrier mother.

The absence of an index fingernail rarely affects a patient's ability to perform functions. COIF is of cosmetic importance, but its prognosis is excellent. Identification of the syndrome and reassurance of the patient and parents are all that is necessary.

Key words: congenital onychodysplasia of the index fingers, hepatitis B virus, Iso-Kikuchi syndrome, nail dysplasia.

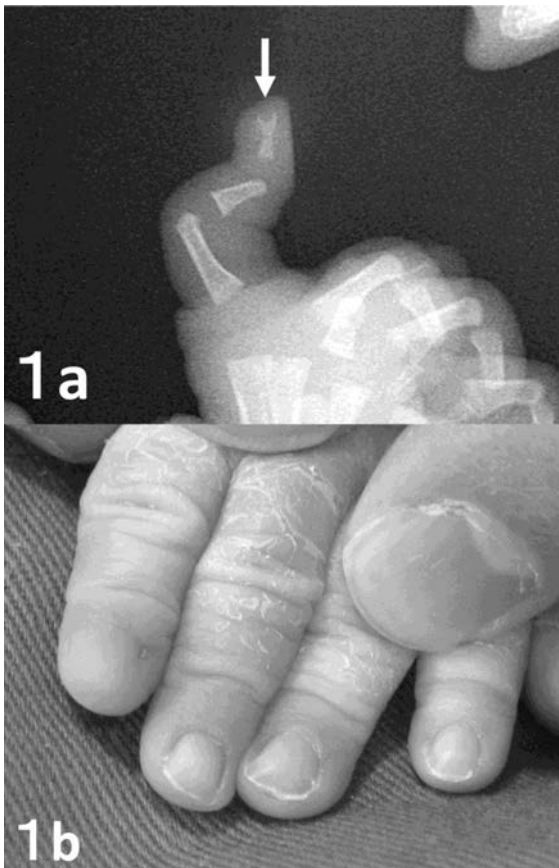


Fig. 1. a. Radiograph shows Y-shaped bifurcation on lateral view on the left index digit, marked by an arrow. b: Micrynychia on the ulnar aspect of the left index finger.

REFERENCES

1. Franceschini P, Licata D, Guala A, Di Cara G, Franceschini D. Peculiar facial appearance and generalized brachydactyly in a patient with congenital onychodysplasia of the index fingers (Iso-Kikuchi syndrome). *Am J Med Genet* 2001; 98: 330-335.
2. Thappa DM, Shivaswamy KN. Polyonychia in congenital onychodysplasia of the index finger (Iso and Kikuchi syndrome): a report from India. *J Dermatol* 2002; 29: 603-605.
3. Hussein TP, Brandt HR, Gabbi TV, Nico MM. Malformations of the index nails. *Clin Exp Dermatol* 2009; 34: 890-891.
4. Padmavathy L, Rao L, Ethirajan N, Kanthimathi R, Adaikappan M. Iso-Kikuchi syndrome with absence of ring fingers and metacarpal bone abnormality. *Indian J Dermatol Venereol Leprol* 2008; 74: 513-515.
5. Pertusi G, Graziola F, Annali G, et al. Iso-Kikuchi syndrome in an Italian new-born with Y-shaped bifurcation of the index fingers. *Eur J Dermatol* 2011; 21: 423-424.
6. Salem A, Gamil H, Hamed M, Galal S. Nail changes in patients with liver disease. *J Eur Acad Dermatol Venereol* 2010; 24: 649-654.
7. Tran TT. Management of hepatitis B in pregnancy: weighing the options. *Cleve Clin J Med* 2009; 76 Suppl 3: S25-29.