

A case of fucosidosis type II: diagnosed with dysmorphological and radiological findings

Esra Kılıç¹, Mustafa Kılıç², G. Eda Ütine¹, Serap Sivri², Turgay Coskun², Yasemin Alanay¹

Divisions of ¹Medical Genetics, and ²Metabolism, Department of Pediatrics, Hacettepe University Faculty of Medicine, Ankara, Turkey

E-mail: kilickorkmaz@yahoo.com.tr

SUMMARY: Kılıç E, Kılıç M, Ütine GE, Sivri S, Coşkun T, Alanay Y. A case of fucosidosis type II: Diagnosed with dysmorphological and radiological findings. Turk J Pediatr 2014; 56: 430-433.

Fucosidosis is a rare autosomal recessive lysosomal storage disorder in which fucose-containing glycolipids, glycoproteins and oligosaccharides accumulate in tissues, as a result of a deficiency of α -L-fucosidase. In this report we describe clinical, dysmorphological and radiological findings of a boy with this disorder. Developmental delay, skeletal deformities and mild coarsening of the face began at two years of age. Clinical signs typical for fucosidosis evolved over time. Psychomotor deterioration progressed slowly. At age 12, he could not walk without help; he was admitted to the hospital with intellectual disability, short stature and coarse facial features. A skeletal survey showed dysostosis multiplex. Cranial MRI demonstrated high intensities on the periventricular white matter and low intensities on the basal ganglia on T2-weighted images. Despite the absence of angiokeratoma on the skin, type II fucosidosis with clinical, dysmorphological and radiological signs was suspected. The diagnosis was established on the basis of severely decreased activity of α -L-fucosidase in the leukocytes. The natural history and specific dysmorphic and radiological findings should, even in the absence of angiokeratoma, assist in the differential diagnosis of this rare condition when lysosomal storage disorders are suspected, particularly in populations in which consanguineous marriages are common.

Key words: fucosidosis, MRI, coarse face, dysostosis multiplex, psychomotor deterioration.

Fucosidosis (OMIM 230000) is a very rare autosomal recessive lysosomal storage disorder due to deficient α -L-fucosidase activity, which hydrolyzes fucose during glycolipid and glycoprotein metabolism.¹ Deficiency of this enzyme results in the accumulation of fucose-containing glycolipids, glycoproteins and oligosaccharides in the lysosomes of the brain, skin and other organs and in urinary excretion of partially degraded oligosaccharides. The *FUCA1* gene on chromosome 1p34 regulates the level of α -L-fucosidase in plasma.² The typical clinical findings are progressive growth and psychomotor retardation, coarse facies, dysostosis multiplex, neurological deterioration and skin angiokeratomas. Two subtypes have been described. Type I is rapidly progressive and fatal in infancy, while type II is slightly milder, resulting in death in adulthood.³ There

is no definitive treatment for fucosidosis. It has been suggested that early bone marrow transplantation is effective.⁴ Clinical and radiological findings of a new case of type II fucosidosis are presented in this report.

Case Report

The patient was born as the second child of consanguineous parents (second-degree cousins) at term following an uneventful pregnancy. His birth size and early developmental milestones were normal until two years of age (Fig. 1a). He then began to deteriorate in all developmental fields. At age four he was referred for moderate developmental and speech delay. He moved slowly and had decreased social interaction (Fig. 1b). At that time thyroid function tests and urine mucopolysaccharides analysis were normal. There was mild coarsening of the

face, with mild dysostosis multiplex on X-rays (vertebral beaking, shallow acetabuli and a J-shaped sella). These signs and symptoms suggested a storage disease, but a definitive diagnosis was not established. He was lost to follow-up until age 12.

On his second admission, at age 12, he had deteriorated significantly. There was intellectual delay with no speech, an inability to walk without support and an evident pattern of behavioral irritability. The facial features had coarsened over time with edematous eyelids, anteverted, prominent nostrils, thickened lips, a shallow philtrum, gingival hypertrophy and short stature. (Fig. 1c, d). There was no visceromegaly, and echocardiography was normal. Dermatological evaluation showed no angiokeratoma. A skeletal survey revealed severe vertebral beaking, shallow acetabuli, mild hypoplasia of the medial distal radius, and mild cortical thinning of the metacarpal bones (Fig. 2a, b, c). Brain MRI showed symmetric periventricular white-matter high intensities contrasting with low intensities on the basal ganglia on T2 weighed images, which is highly typical for lysosomal storage diseases (Fig. 3). Neither cerebral nor cerebellar atrophy was present. Urine glycosaminoglycan analysis was normal. Fucosidosis was suspected as the possible diagnosis based on clinical history and dysmorphic and radiographic findings. Lysosomal enzyme activity in the leukocytes later showed markedly deficient 0.15 $\mu\text{mol/g/h}$ (reference range: 50-200) α -L-fucosidase activity. The family declined molecular testing.

Considering the slowly progressive course of the disease, on the bases of the signs and symptoms, a diagnosis of fucosidosis type II was established.

Discussion

Fucosidosis is an extremely rare lysosomal storage disorder that is due to deficiency of the enzyme α -L-fucosidase and results in the accumulation of fucose-containing glycolipids, glycoproteins and oligosaccharides in the lysosomes of the brain, skin and the other organs, leading to a severe neurodegenerative disorder, often with seizures and mild dysostosis.¹ It is inherited through an autosomal recessive pattern, and more than 22 mutations of the *FUCA1* gene have been identified as resulting in fucosidosis.² Affected individuals often exhibit prominent, widespread angiokeratomas. Similar to other oligosaccharidoses, the clinical course can be variable, making early diagnosis difficult.

Over time, multisystemic progressive substance accumulation leads to progress in symptoms and signs. The main clinical features are progressive neurologic deterioration (95%), coarse facial features (79%), growth retardation (78%), seizures (38%), recurrent sinopulmonary infections (78%), visceromegaly (44%), angiokeratoma corporis diffusum (52%) and dysostosis multiplex (58%).³ There is considerable heterogeneity in clinical presentation, even in members of the same family. A comparison of the clinical findings of the previous study and our case is given in Table I. Although there is no precise clinical

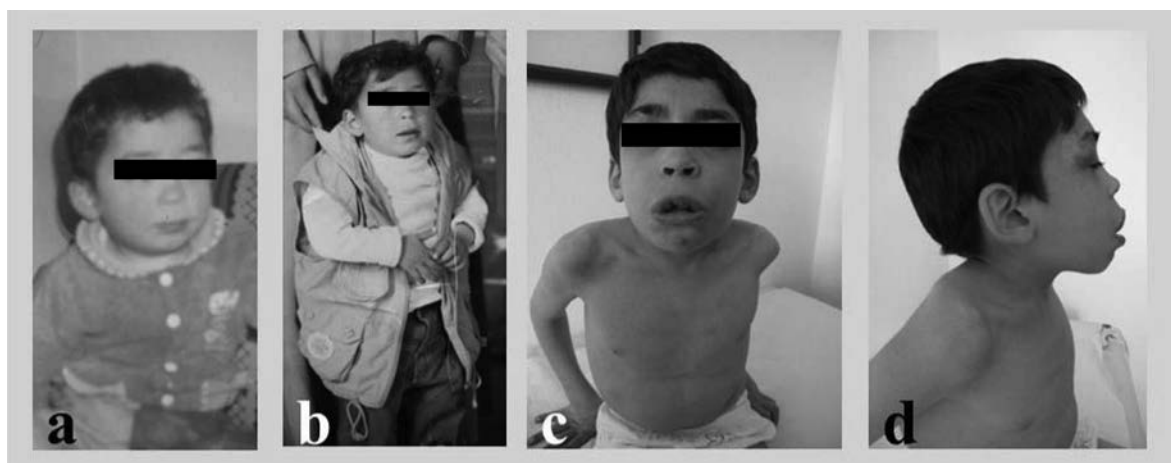

Fig. 1. The progression of coarsened facial features and disease from 4 to 12 years of age.

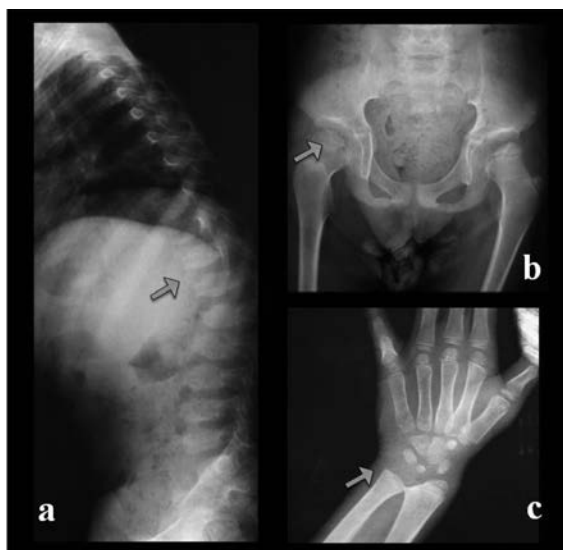

Fig. 2. Dysostosis multiplex (a. Vertebral beaking, b. Shallow acetabulum and c. Mild hypoplasia of medial distal radius, and mild cortical tinning of metacarpal bones) on X-ray.

distinction, historically two clinical subtypes of fucosidosis have been delineated. Type I is the rapidly progressive form, beginning before one year of age, leading to rapid neurological deterioration, seizures, growth retardation and visceromegaly. Death occurs in the first decade. Type II is the slowly progressive form, with onset usually before age two and a slower advance of neurologic deterioration, spasticity and angiokeratomas. Most individuals survive to ages 20-40. Type I and type II fucosidosis represent the extreme poles of a continuous clinical spectrum. Williams et al.³ reviewed findings of 77 fucosidosis patients; 17 of 77 cases were symptomatic before age one, and 14 of these individuals died before age 10. No associations exist between disease severity and

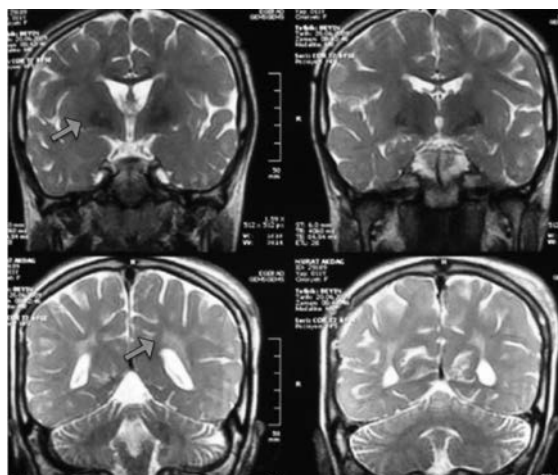


Fig. 3. Cranial MRI at 12 years of age shows high intensities on the periventricular white matter and low intensities on the basal ganglia on coronal T2 weighted images.

specific mutation or the level of residual enzyme activity.^{1,3} The demonstration of reduced α -L-fucosidase activity in the leukocytes or in cultured fibroblasts permits diagnosis in both subtypes. Molecular analysis of *FUCA1*, the structural gene of α -L-fucosidase, and *FUCA2*, which regulates the level of α -L-fucosidase in plasma, provides unequivocal diagnosis.

In the patient presented here, regression after an early normal development and slowly progressive mental and motor deterioration, facial coarsening and dysostosis multiplex in addition to abnormal urinary oligosaccharides with extremely low α -L-fucosidase activity established the diagnosis of type II fucosidosis. Although angiokeratoma is generally considered a typical sign for fucosidosis, it is present in only 40-52% of fucosidosis patients in the literature.^{3,5} The presence or absence of

Table I. Comparison of Clinical Features with the Literature

Clinical features	Willems et al. ³	Present Case
Mental deterioration	95%	+
Motor deterioration	87%	+
Coarse facies	79%	+
Growth retardation	78%	+
Recurrent infections	78%	-
Dysostosis multiplex	58%	+
Angiokeratoma corporis diffusum	52%	-
Visceromegaly	44%	-
Seizures	38%	-

angiokeratoma more likely depends on the patient's age. Consequently, angiokeratoma is reported mostly in type II patients. In the second decade, angiokeratoma is reported in 75% of patients.³ In the present patient, there was still no angiokeratoma at age 12. The absence is therefore noteworthy in that as it underlines the fact that the presence of other suggestive findings should also lead to accurate diagnosis.

In the literature, MRI findings of fucosidosis are progressive white-matter signal alterations in the periventricular and subcortical areas, various degrees of cerebral and cerebellar atrophy depending on disease progression, and low signal intensities on the basal ganglia on T2-W images.⁶ Although the mechanism underlying these signal alterations is unknown, several possible causes including calcification, iron deposition following subacute hemorrhage, accumulating paramagnetic substances such as manganese and cerebral glycolipid accumulation have been discussed.⁷ The MRI findings in the presented patient are compatible and highly suggestive for fucosidosis.

About 100 cases of fucosidosis (types I and II) have been described in the literature so far.⁸ Despite the high rate of consanguineous marriage in Turkey, fucosidosis is nonetheless among the very rare diseases. There is no complete cure for fucosidosis, although early hematopoietic stem cell transplantation in presymptomatic patients may be successful.⁴

Although patients with fucosidosis are comparatively lacking in the typical facial dysmorphism and mild dysostosis seen in the other lysosomal storage disorders, pediatricians should suspect fucosidosis when dysmorphological and radiological signs exist, even if angiokeratoma is absent. Consequently, especially in the presence of parental consanguinity, rare autosomal recessive diseases should be kept in mind and diagnostic investigations for lysosomal disorders performed in patients with progressive neurologic deterioration, coarse facial features and dysostosis multiplex.

REFERENCES

1. Wraith J. Mucopolysaccharidoses and oligosaccharidoses. In: Fernandes J, Saudubray JM, van den Berg G, Walter JH (eds). *Inborn Metabolic Diseases* (4th ed). Germany: Springer; 2006: 497-507.
2. Willems PJ, Seo HC, Coucke P, Tonlorenzi R, O'Brien JS. Spectrum of mutations in fucosidosis. *Eur J Hum Genet* 1999; 7: 60-67.
3. Willems PJ, Gatti R, Darby JK, et al. Fucosidosis revisited: a review of 77 patients. *Am J Med Genet* 1991; 38: 111-131.
4. Miano M, Lanino E, Gatti R, et al. Four year follow-up of a case of fucosidosis treated with unrelated donor bone marrow transplantation. *Bone Marrow Transplant* 2001; 27: 747-751.
5. Ben Turkia H, Tebib N, Azzouz H, et al. Phenotypic spectrum of fucosidosis in Tunisia. *J Inherit Metab Dis* 2008; 2: 313-316.
6. Prietsch V, Arnold S, Kraegeloh-Mann I, Kuehr J, Santer R. Severe hypomyelination as the leading neuroradiological sign in a patient with fucosidosis. *Neuropediatrics* 2008; 39: 51-54.
7. Galluzzi P, Rufa A, Balestri P, Cerase A, Frederico A. MR brain imaging of fucosidosis type I. *Am J Neuroradiol* 2001; 22: 777-780.
8. Kanitakis J, Allombert C, Doebelin B, et al. Fucosidosis with angiokeratoma. Immunohistochemical & electronmicroscopic study of a new case and literature review. *J Cutan Pathol* 2005; 32: 506-511.