

Successful noninvasive mechanical ventilation in a child on prolonged and life-threatening invasive mechanical ventilation after Fontan operation

Ayhan Yaman¹, Tanıl Kendirli¹, Çağlar Ödek¹, Cem Karadeniz², Tayfun Uçar², Gülnur Göllü³, Zeynep Eyileten⁴, Erdal İnce¹

Divisions of ¹Pediatric Intensive Care Unit, ²Pediatric Cardiology, Department of Pediatrics and Department of ³Pediatric Surgery, and ⁴Cardiovascular Surgery, Ankara University School of Medicine, Ankara, Turkey.

E-mail: dryamanayhan@yahoo.com.tr

SUMMARY: Yaman A, Kendirli T, Ödek Ç, Karadeniz C, Uçar T, Göllü G, Eyileten Z, İnce E. Successful noninvasive mechanical ventilation in a child on prolonged and life-threatening invasive mechanical ventilation after Fontan operation. Turk J Pediatr 2014; 56: 111-114.

For many decades, the primary treatment of acute respiratory failure has been mechanical ventilation. Intubation and mechanical ventilation carry complications such as upper respiratory system trauma, barotrauma, volutrauma, oxytrauma, atelectrauma, and nosocomial infection, and they increase mortality. Noninvasive mechanical ventilation (NIMV) applied to a specially selected group of patients has more advantages than invasive ventilation, especially the decreased number of complications. We present a three-year-old girl who had prolonged invasive mechanical ventilation (IMV) and weaning failure due to severe tracheal bleeding after Fontan operation. She could not be extubated for 20 days after admission to our Pediatric Intensive Care Unit (PICU) because of life-threatening airway bleedings from within the endotracheal tube. Owing to the severe bleedings during endotracheal aspirations, it was decided to change her mechanical ventilation to NIMV. NIMV was performed successfully for 12 days without difficulty, and she was discharged from the hospital on the 55th postoperative day with normal clinical findings. Noninvasive ventilation has an increasing use in critically ill children. NIMV should be considered in prolonged mechanical ventilation and weaning failure from IMV in critically ill children.

Key words: noninvasive mechanical ventilation, Fontan operation, prolonged invasive mechanical ventilation, children.

Noninvasive mechanical ventilation (NIMV) has primarily been applied in patients with acute exacerbations of chronic obstructive pulmonary disease, cardiogenic pulmonary edema and hypoxemic respiratory failure¹⁻⁴. In recent years, NIMV has also been used to prevent the occurrence of acute respiratory failure after surgery (prophylactic use) or to treat acute respiratory failure (therapeutic use)^{5,6}. NIMV facilitates early extubation and improves the outcome in selected patients with an exacerbation of chronic obstructive pulmonary disease and weaning failure⁷. NIMV use in critically ill children has increased recently especially in pediatric intensive care units (PICUs). Pediatric intensivists use it for

prevention of intubation, extubation failure and reintubation.

We present herein a three-year-old girl with prolonged MV and persistent weaning failure due to bleeding diathesis in the trachea after Fontan operation. She was successfully ventilated by NIMV.

Case Report

A three-year-old girl was admitted to our PICU after Fontan procedure. According to her medical records, pulmonary atresia, intact interventricular septum, right ventricle-dependent coronary circulation, hypoplastic right ventricle, and tricuspid hypoplasia were diagnosed by echocardiography for postnatal

cyanosis on the first day of life. A modified Blalock-Taussig shunt was performed on the postnatal 9th day, which was followed by Glenn operation at the age of 18 months.

When she was three years old, Fontan operation was performed as the third operation. The cross-clamp and bypass times were 100 and 120 minutes during the operation, respectively. Intraoperative bleeding was a challenge and was controlled with difficulty. Postoperatively, the patient received supportive high-dose inotropic agents such as adrenalin, dopamine and milrinone in the PICU.

The postoperative laboratory results revealed normal complete blood count, biochemical parameters and acute phase reactants. Prothrombin time was 14.9 seconds (Normal: 9.4–12.5 seconds), whereas activated partial thromboplastin time was 33 seconds (Normal: 25.1–36.5 seconds). International normalized ratio was recorded as 1.13.

The patient received only milrinone, for which the need decreased on the 3rd day of PICU admission. Arterial blood gases and chest X-ray were normal on the follow-up, and she was extubated. The patient showed increased respiratory distress two days after extubation, which was demonstrated with hypoxia and hypotension. She had to be reintubated due to respiratory and cardiovascular system deterioration. Her hemodynamics did not improve during the follow-up, and her liver enlarged to 8 cm from the subcostal line. Her liver function tests revealed high levels for total

bilirubin (4 mg/dl), aspartate aminotransferase (1300 U/L) and alanine aminotransferase (1100 U/L) due to congestion. A graft thrombosis was suspected and heparin infusion was started. One day later, massive pulmonary bleeding occurred. There were bilateral consolidations in the lungs due to pulmonary hemorrhage and edema (Fig. 1). Her heparin was stopped immediately and protamine sulphate was administered. Platelet suspension and fresh frozen plasma support was given. Elevated liver enzymes returned to normal values after nine days. Although spontaneous bleeding stopped, post-aspiration bleedings continued. The detailed examinations of bleeding diathesis revealed prolonged *in-vitro* bleeding time using the collagen-adenosine diphosphate - platelet function assay-100 (Col-ADP - PFA-100) as 160 seconds (Normal range: 68–121) and low factor VII level (10.8%, Normal range: 50–129%). The patient was monitored in MV throughout the follow-up, which lasted 20 days. We observed life-threatening bleedings during endotracheal aspirations. The patient could not be extubated. Bronchoscopy was performed, which demonstrated widespread hyperemia, loss of mucosa, numerous bleeding sources, and mucosal bleedings throughout the airways. Due to the patient's bleeding diathesis, iatrogenic

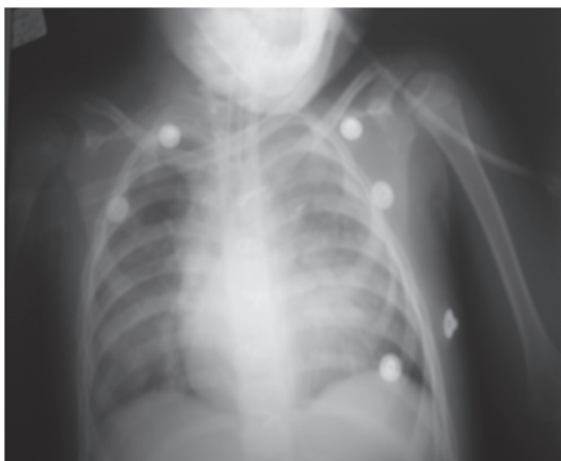

Fig. 1. Chest X-ray taken after the patient's massive pulmonary hemorrhage.

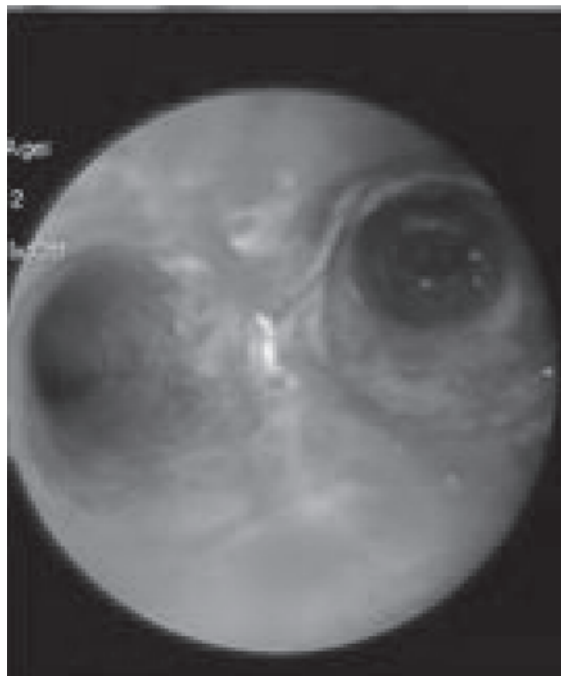


Fig. 2. Patient's bronchoscopy revealed fragility and mucosal bleedings in the trachea and main bronchus.

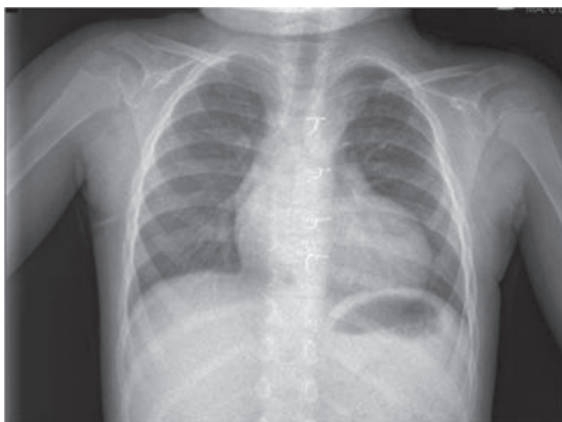

Fig. 3. Chest X-ray after extubation and eight days of noninvasive ventilation.

bleeding or necrotizing tracheobronchiolitis was suspected. Argon was applied to control the severe bleeding (Fig. 2).

She was aspirated with low-pressured endotracheal aspirations due to the life-threatening airway bleedings under IMV. We planned to attempt NIMV to prevent endotracheal aspirations and any related mortality. The patient was extubated two days later and noninvasive bilevel positive airway pressure (BiPAP) mode respiratory support was provided.

Noninvasive mechanical ventilation (NIMV) support was performed with the BiPAP S/T (Spontaneous/Time) mode. Initial BiPAP settings were as follows: IPAP (inspiratory peak airway pressure) 14 cmH₂O and EPAP (expiratory peak airway pressure) 7 cmH₂O. However, in order to provide efficient ventilation to the patient, IPAP was increased to 25 cmH₂O and EPAP was increased to 10 cmH₂O. The patient's oxygen saturation showed above 92%. Blood gases were in normal ranges during the follow-up, and there was no atelectasis or infiltration in the chest radiography. No bleeding developed at that moment. NIMV support was sustained for 12 days, and the patient improved daily with this support. The patient did not require any reintubation on the follow-up.

The patient's chest radiography was normal after noninvasive ventilation (Fig. 3). The patient was discharged from the PICU on the 35th day of admission. She was discharged from the children's hospital on the 55th postoperative day with normal clinical findings.

Discussion

For many decades, the primary treatment of acute respiratory failure has been MV support using endotracheal intubation. MV and endotracheal intubation carry complications such as upper respiratory system trauma, barotrauma, volutrauma, oxytrauma, atelectrauma, and nosocomial infections. Correspondingly, NIMV is more comfortable, offers mobility, decreases MV complications, and permits oral feeding⁸. At first, our patient was followed under IMV, but life-threatening airway bleedings occurred. NIMV was thus considered, and resulted in successful ventilation without any life-threatening bleeding.

Noninvasive mechanical ventilation (NIMV) has also been used to prevent the occurrence of acute respiratory failure after surgery (prophylactic use) or to treat acute respiratory failure (therapeutic use)^{5,6}. NIMV facilitates early extubation and improves the outcome of selected patients with an exacerbation of chronic obstructive pulmonary disease and weaning failure⁷. Epstein et al.⁹ showed that NIMV was effective in preventing the occurrence of post-extubation failure in patients at risk. Our patient had high-risk post-extubation failure, but with the support of the NIMV, reintubation was avoided.

Noninvasive mechanical ventilation (NIMV) refers to techniques allowing respiratory support without the need for an invasive airway management. Two types of NIMV are commonly used: noninvasive continuous positive airway pressure (CPAP) and BiPAP. This pressure-targeted type of NIMV gives respiratory support at two levels: the IPAP and EPAP¹⁰. We applied BiPAP mode as NIMV with high IPAP and EPAP levels because the patient was developing atelectasis when we reduced the PAP. The patient received noninvasive respiratory support for 12 days and improved daily. Our patient had good compliance and no complication under high-pressure NIMV.

Postoperative pulmonary complications (PPCs) in congenital heart disease surgery are generally defined as any pulmonary abnormality occurring in the postoperative period. PPCs can include atelectasis, postoperative pneumonia, pulmonary edema, and acute respiratory failure¹¹. They may increase hospital length of stay, morbidity and mortality¹². In the presented

patient, there was intraoperative difficulty in controlling bleeding from surgical areas. She had a tendency to mucosal bleeding, especially in the trachea, because of her prolonged cross-clamp and bypass times, and then severe damage developed in the airways. After cardiac surgery, the patient needed prolonged IMV (for 20 days), and life-threatening airway bleeding and severe hemodynamic instability developed.

Early extubation of patients after surgical attempts in congenital heart disease is very important. Since the right ventricle is non-functional after the Fontan procedure, pulmonary blood flow, and therefore, right heart volume, depend on passive and non-pulsatile systemic venous pressure. Positive-pressure MV reduces systemic and pulmonary venous blood flow to the lung. Controlled hypoventilation and mild hypercapnia increase capopulmonary blood flow during MV of these patients¹³. Our patient was extubated three days after her admission to the PICU. However, upon an increase in respiratory distress and the development of hypoxia and hypotension, she had to be reintubated within two days.

In conclusion, NIMV shows an increasing use in critically ill children in PICUs. NIMV can be considered in prolonged MV and weaning failure from IMV. In our patient, we found NIMV to be lifesaving. NIMV should be used more in PICUs in selected cases, especially in children.

REFERENCES

1. British Thoracic Society Standards of Care Committee. Non-invasive ventilation in acute respiratory failure. *Thorax* 2002; 57: 192-211.
2. Evans TW, International Consensus Conferences in Intensive Care Medicine: non-invasive positive pressure ventilation in acute respiratory failure. Organised jointly by the American Thoracic Society, the European Respiratory Society, the European Society of Intensive Care Medicine, and the Societe de Reanimation de Langue Francaise, and approved by the ATS Board of Directors, December 2000. *Intensive Care Med* 2001; 27: 166-178.
3. Ferrer M. Non-invasive ventilation in the weaning process. *Minerva Anesthesiol* 2008; 74: 311-314.
4. Nava S, Navalesi P, Carlucci A. Non-invasive ventilation. *Minerva Anesthesiol* 2009; 75: 31-36.
5. Ferreyra G, Long Y, Ranieri VM. Respiratory complications after major surgery. *Curr Opin Crit Care* 2009; 15: 342-348.
6. Jaber S, Chanques G, Jung B. Postoperative noninvasive ventilation. *Anesthesiology* 2010; 112: 453-461.
7. Nava S, Ambrosino N, Clini E, et al. Noninvasive mechanical ventilation in the weaning of patients with respiration failure due to chronic obstructive pulmonary disease: a randomized, controlled trial. *Ann Intern Med* 1998; 128: 721-728.
8. Eren NT, Batislam Y. Noninvasive positive pressure ventilation. *J Ankara Medical School* 1996; 18: 49-52.
9. Epstein SK, Ciubotaru RL. Independent effects of etiology of failure and time of reintubation on outcome for patients failing extubation. *Am J Respir Crit Care Med* 1998; 158: 489-493.
10. Pelosi P, Jaber S. Noninvasive respiratory support in the perioperative period. *Curr Opin Anaesthesiol A* 2010; 23: 23-28.
11. Arozullah AM, Daley J, Henderson WG, Khuri SF. Multifactorial risk index for predicting postoperative respiratory failure in men after major noncardiac surgery. The National Veterans Administration Surgical Quality Improvement Program. *Ann Surg* 2000; 232: 242-253.
12. O'Donohue WJ. Postoperative pulmonary complications. When are preventive and therapeutic measures necessary? *Postgrad Med* 1992; 91: 167-175.
13. Alexandre TR, Peter CL, David LW. Critical care after surgery for congenital cardiac disease. In: Furhman BP, Zimmerman J, Carcillo JA, et al. (eds). *Pediatric Critical Care* (4th ed). St. Louis: Elsevier; 2011: 423-425.