

Adenomyoma of the small intestine in children: a rare cause of intussusception A case report

Vassilios Mouravas¹, Georgios Koutsoumis¹, John Patoulis¹, Ioannis Kostopoulos²
Rodosula Kottakidou³, Kanstantinos Kallergis¹, Chrysostomos Kepertis¹, Nikolaos Liolios¹

Departments of ¹Pediatric Surgery, and ²Pathology, Aristotle University of Thessaloniki and ³Histopathology Laboratory, General Hospital "G. Gennimatas", Thessaloniki, Greece.

SUMMARY: Mouravas V, Koutsoumis G, Patoulis J, Kostopoulos I, Kottakidou R, Kallergis K, Kepertis C, Liolios N. Adenomyoma of the small intestine in children: a rare cause of intussusception. A case report. Turk J Pediatr 2003; 45: 345-347.

Adenomyomas are hamartomas of the alimentary tract with exceptionally rare localization at the ileum. The case presented here concerns an infant aged 18 months suffering from adenomyoma of the ileum, which was responsible for the development of ileoileac intussusception. Our paper aims at underlining the particularities of this extremely rare entity, while adding the 13th case reported to the international bibliographic references.

Key words: adenomyoma, myoepithelial hamartoma, children, intussusception.

Adenomyomas are rare hamartomas of the alimentary tract, consisting of glandular structures covered with mucosecretory cylindrical epithelium and surrounded by smooth muscle bundles¹⁻³. Although most cases refer to adults, they may also appear at any age. The first description of adenomyomas was that of Magnus Alsleben, in 1903, and concerned localization at the stomach⁴. Since that time, there have been only a few reported cases, the vast majority of which have been located at the propyloric segment of the stomach⁵. Their localization at the small intestine of young patients is considered extremely rare, since we could locate only 12 cases described in the international literature available to us (Table I).

The case presented here concerns a young patient aged 18 months suffering from adenomyoma of the ileum that caused intussusception. We also review the international literature.

Case Report

A male infant, aged 18 months, was admitted in our hospital with abdominal pain, distension, bilious vomiting, and bloody stools, which had appeared 12 hours prior to admission. The plain abdominal X-ray showed multiple air fluid levels of the small intestine, and the abdominal ultrasound revealed intussusception at the terminal ileum. Following the required preoperative preparation and support, the young

Table I. Reported Pediatric Cases of Adenomyoma in the English Language Literature

Study	Year	Reference	Gender	Age	Situation	Main clinic picture
1 Clarke BE ²	1940	Arch Pathol	Male	15 years	MD	Intussusception
2 Rosenman E et al. ⁶	1980	J Med Sci	Female	2 days	Ileus	Intestinal obstruction
3 Kim CJ et al. ⁷	1990	Pediatr Pathol	Male	7 years	Ileus	Intussusception
4 Gal R et al. ⁵	1991	Histopathol	Male	9 months	Ileus	Intussusception
5 Serour F et al. ⁹	1994	J Pediatr Gastroenterol Nutr	Male	4 years	Ileus	Intussusception
6 Chan YF et al. ³	1994	J Pediatr Surg	Female	5 months	Ileus	Intussusception
7 Montgomery E et al. ¹²	1994	Hum Pathol	4 cases in children	Unknown	Ileus	Intussusception
8 Yao JL et al. ¹³	2000	Pediatr Develop Pathol	Male	22 months	MD	Intussusception

MD: Meckel's diverticulum.

patient was transferred to an operating theater and underwent exploratory laparotomy. An ileoileac intussusception was found, with a 4 cm long allantois, and disintussusception was performed. Part of the disintussuscepted intestine, 4 cm long, was considered non-viable, and enterectomy and end to end ileoileal anastomosis are carried out. The pathology examination showed an exophytic mass at the top of the intussusception sized 1.5 cm x 1 cm, which was causing the intussusception. It consisted of dilated glandular structures, covered by monolayer cylindrical epithelium, surrounded by smooth muscles bundles (Fig. 1) and was located at the submucosa (Fig. 2). The presence of smooth muscle cells was identified by immunohistochemical techniques which demonstrated strong desmin immunoreactivity in the cytoplasm of these cells. No ectopic pancreatic tissue was found. These findings were compatible with the diagnosis of adenomyoma of the small intestine. At other areas, the

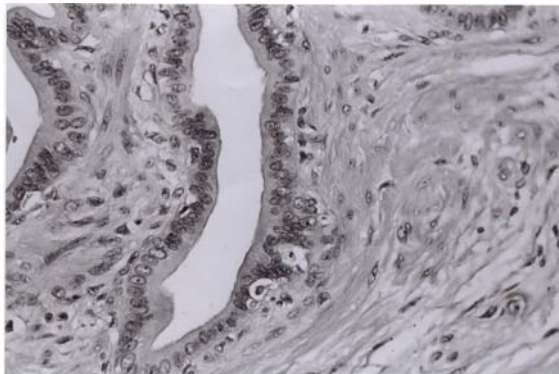


Fig. 1. Histological image, a brown structure projecting to the lumen, 1.5 cm in largest diameter was noticed.

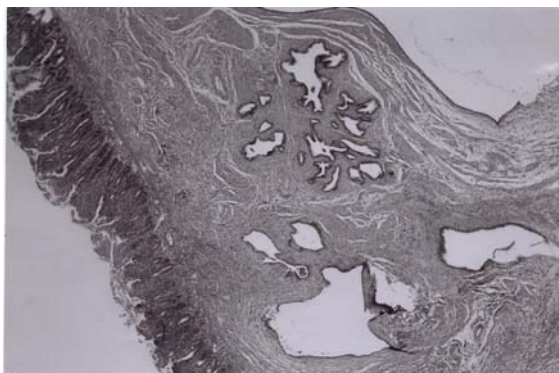


Fig. 2. Histological image with the dilated glandular structures covered by monolayer cylindrical epithelium and surrounded by bundles of smooth myofibrils.

resected specimen presented mucosal ulcerations and locally bloody infarcts resulting from intussusception.

The young patient recovered easily after the surgery, and had a normal postoperative course.

Discussion

Adenomyomas of the gastrointestinal tract are rare lesions localized at the stomach, the duodenum and the biliary ducts⁵. Usually, they occur asymptotically. Other names have also been used to describe them, such as myoepithelial hamartoma^{3,6} and foregut choristoma⁷. With regard to their origin, they are either considered epithelial hamartomas or ectopic pancreatic tissue, where smooth muscle bundles and elements of gland ducts predominate^{2,7,8}.

Their localization at the small intestine of children is extremely rare (Table I). Intussusception is the most common complication of adenomyoma of the small intestine, as was the case with our patient. Thus far, of the 12 reported cases of adenomyoma in children, only two did not cause intussusception: in one case, intestinal obstruction preceded⁶, and the other concerned an incidental finding³.

It is important that adenomyoma be distinguished from enteritis cystica profunda, pneumatosis cystoides intestinalis, hamartomatous polyp of Peutz-Jeghers syndrome, duplication cyst, and adenocarcinoma^{5,9}. The last is especially true if the specimen is from an adult patient with obstructive symptoms, either intestinal or biliary, and is sent for frozen section. An awareness of this entity will allow adenomyoma to be kept in the differential diagnosis and spare the patient needless radical surgery¹⁰.

As for their obvious rarity, there is an expressed view that this may be due to the lack of report of these cases³ or to false diagnosis⁵. The lack of references in the modern international literature other than what we have pointed out, as well as the typical histological image of adenomyoma, which does not easily allow for confusion with other entities, increase our conviction that it is really about very rare localizations of this benign lesion at the ileum^{7,9,11,12}.

REFERENCES

1. Dawson I. Hamartomas in the alimentary tract. Gut 1969; 10: 691-694.
2. Clarke BE. Myoepithelial hamartoma at the gastrointestinal tract. A report of eight cases with comment concerning genesis and nomenclature. Arch Pathol 1940; 30: 143-152.

3. Chan YF, Roche D. Adenomyoma at the small intestine in children. *J Pediatr Surg* 1994; 29: 1611-1612.
4. Magnus-Alsleben E. Adenomyome de pylorus. *Virchows Arch Pathol Anat* 1903; 173: 137-156.
5. Gal R, Rath-Wolfson L, Ginzburg M, Kessler E. Adenomyomas of the small intestine. *Histopathology* 1991; 18: 369-371.
6. Rosenman E, Maayan C, Lernam O. Leiomyomatohamartosis with congenital jejunoileal atresia. 1st. *J Med Sci* 1980; 10: 775-779.
7. Kim CJ, Chal GY, Chi JG. Foregut choristoma at the ileum (adenomyoma)-a case report. *Pediatr Pathol* 1990; 10: 700-805.
8. Bahal P, Zaviacic M, Danihel L. Evidence that adenomyoma at the duodenum is ectopic pancreas. *Histopathol* 1998; 33: 487-488.
9. Serour F, Gorenstein A, Lipnitzky V, Zaidel L. Adenomyoma of the small bowel: a rare case of intussusception in childhood. *J Pediatr Gastroenterol Nutr* 1994; 18: 247-249.
10. Marein R, Gal R, Kyzer S, Feizman Z, Shapira G, Mittleman M. Severe weight loss, renal failure and metabolic alkalosis due to duodenal adenomyoma. *Am J Gastroenterol* 1993; 88: 472-473.
11. Chapple CR, Muller S, Newman J. Gastric adenocarcinoma associated with adenomyoma at the stomach. *Postgrad Med J* 1988; 64: 801.
12. Montgomery E, Popek E. Intussusception, adenovirus and children. A brief reaffirmation. *Hum Pathol* 1994; 25: 169-174.
13. Yao JL, Zhou H, Roche K, Bangaru BS, Ginsburg H, Greco MA. Adenomyoma arising in a meckel diverticulum: case report and review of the literature. *Pediatr Dev Pathol* 2000; 3: 497-500.