

Temporary atrioventricular complete block that develops following the transcatheter closure of ventricular septal defect

Sevcan Erdem, Alev Kızıldaş, Osman Küçükosmanoğlu, Nazan Özbarlas

Department of Pediatric Cardiology, Çukurova University Faculty of Medicine, Adana, Turkey

SUMMARY: Erdem S, Kızıldaş A, Küçükosmanoğlu O, Özbarlas N. Temporary atrioventricular complete block that develops following the transcatheter closure of ventricular septal defect. Turk J Pediatr 2012; 54: 80-82.

Atrioventricular (AV) block is a potential risk after transcatheter closure of perimembranous ventricular septal defect (VSD) with the Amplatzer perimembranous device. We present herein a case of a 6.5-year-old female patient who developed complete AV block six days after closure of VSD and recovered with steroid and salicylate treatment. It is important to be alert to the development of AV block after transcatheter perimembranous VSD closure. Very careful monitoring of rhythm is mandatory during the short- and long-term follow-up.

Key words: transcatheter ventricular septal defect closure, atrioventricular block, pacemaker, anti-inflammatory treatment.

Ventricular septal defect (VSD) is the most common congenital heart disease¹. Transcatheter methods for closure of muscular VSD are applied as a good alternative to surgical treatment in eligible patients²⁻⁵. However, in perimembranous type defects, it is debatable due to the risk of atrioventricular (AV) block development following transcatheter closure. The AV block may occur during or after the transcatheter closure, at a frequency of 1-5%^{6,7}. In some cases, the AV block may occur days or even months after the operation. Herein, we present the case of a 6.5-year-old female patient who developed complete AV block with syncope six days after the uneventful closure of perimembranous VSD; she recovered with steroid and salicylate treatment.

Case Report

A 6.5-year-old girl, weighing 20 kg, underwent an elective transcatheter closure of perimembranous outlet VSD. Before the procedure, she had no other significant medical history. Her ECG showed sinus rhythm and did not show any conduction abnormalities. The defect was measured as 5 mm via transthoracic echocardiography (TTE). The left ventricle was slightly dilated, and there was a small left ventricle-right atrial communication. The

defect was closed through a standard method under general anesthesia by fluoroscopy and transesophageal echocardiography (TEE) with 6 mm membranous VSD occluder device (Amplatzer, AGA Medical, Golden Valley, Minnesota, USA) without any procedural complication. No arrhythmias were observed during the procedure. On the TTE, performed one day after the operation, it was observed that the defect was totally closed and there was no rhythm or conduction abnormality. The patient was discharged with acetylsalicylic acid in antiaggregant dosage. Six days after the operation, the patient applied to the hospital due to fatigue and syncope. The ECG showed AV block with low ventricular rate. When the AV block was observed in the ECG, a temporary pacemaker was inserted emergently (Figs. 1, 2). The acetylsalicylic acid dosage was increased to 100 mg/kg/day and dexamethasone was started additionally at a dosage of 1 mg/kg/day. On the third day of the treatment, Holter monitoring showed sinus rhythm and intermittent AV block. On the fifth day, normal sinus rhythm and right bundle branch block pattern were determined, and on the seventh day, the temporary pacemaker was removed (Fig. 3). On the eighth day of the treatment, the medicines were re-

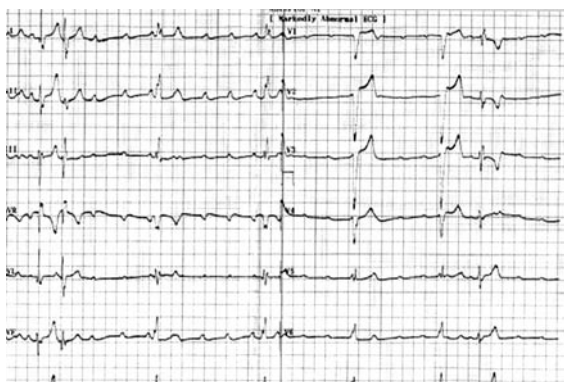


Figure 1. Complete AV block with low ventricular rate.

regulated as 1 mg/kg/day dexamethasone and 80 mg/kg/day acetylsalicylic acid. After the second week, the steroid treatment was decreased and then ceased in the third week. Acetylsalicylic acid was also decreased in the fourth week, and was continued for six months as antiaggregant dosage. At clinical follow-up examinations at 24 months, ECG and Holter monitoring showed sinus rhythm with right bundle branch block.

Discussion

Ventricular septal defect (VSD) is the most common congenital heart disease, and 70% of defects are perimembranous¹. Transcatheter closure of VSDs has emerged recently as a good alternative to surgical repair, with high success rates and low morbidity. Convenient devices were developed in recent years in order to close firstly muscular and then perimembranous defects. However, perimembranous VSD constitutes a special case since the technique for transcatheter closure is more complex

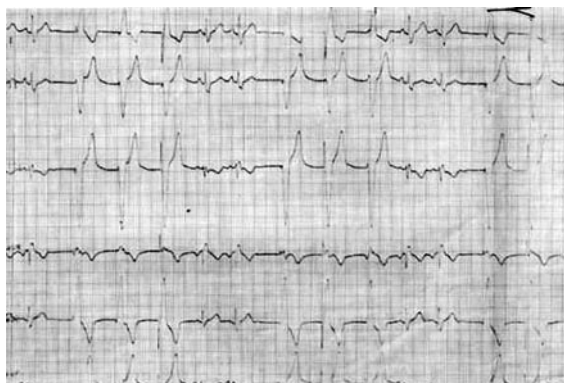

Figure 2. Complete AV block and temporary pace pulses.

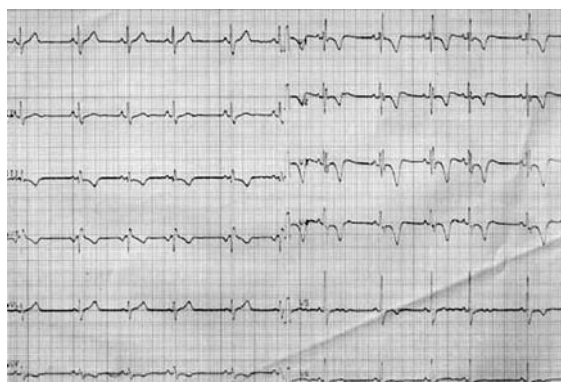

Figure 3. Sinus rhythm and right bundle branch block configuration after the anti-inflammatory treatment.

and hence warrants individual evaluation. Amplatzer membranous VSD occluder is the most frequently used device in the closure of perimembranous defects with transcatheter methods^{6,7}. The device is asymmetrical and adjacent to the conduction system, and rhythm and conduction problems are among the significant complications in closing especially perimembranous defects. Serious rhythm problems can be observed during the procedure or in a few days or even months following the closure. The estimated incidence of complete heart block after transcatheter closure is 1-5%⁶⁻⁸. The real underlying mechanism is not fully understood. During the procedure, the block may occur in the conduction system related to the catheter or the device; if 2nd or 3rd degree AV block has occurred, it is recommended to cease the procedure. After the procedure, it is considered that the block may develop due to edema in the early period or due to inflammation and fibrosis in the late period. The patients should be followed with ECG and Holter monitoring. If there is sufficient ventricular escape rhythm in the patients who developed heart block in the early period, close monitoring and intensive anti-inflammatory treatment may reverse the heart block. A treatment protocol that has been used in many centers is to hospitalize for at least one week for intensive care, high-dose steroid and high-dose acetylsalicylic acid before inserting a permanent pacemaker⁹⁻¹¹. A temporary pacemaker can be inserted until high-dose steroid and acetylsalicylic acid take effect. In some cases in whom anti-inflammatory treatment is ceased earlier, it is reported that complete heart block is repeated.

It is recommended that high-dose treatment should be applied for at least one week and then ceased gradually in two to three weeks¹¹. In non-responsive cases, another treatment option is to remove the device and place a permanent pacemaker.

In a study conducted by Butera et al.⁸, it was reported that in 104 cases with perimembranous VSD closed via transcatheter method, complete heart block developed in the early period in three patients, and in 4, 8, 12, and 20 months after the operation in four patients. In one of the patients, there was response to the anti-inflammatory treatment, but the heart block occurred eight months later. A permanent pacemaker was placed in the four patients with late-period heart block.

It is not accurately known how to prevent complete heart block. Choosing the appropriate-sized device might be an important factor. Walsh et al.¹⁰ suggested that the device selected should be 0.5-1 mm larger than the perimembranous VSD diameter as measured on TEE.

It is not yet clear whether it is necessary to insert a permanent pacemaker in patients with symptomatic AV block who revert to sinus rhythm after steroid treatment. Walsh et al.¹⁰ reported that they inserted a permanent pacemaker in three patients who developed AV block after transcatheter VSD closure that resolved with steroid treatment. Zhou et al.⁹ also reported a patient whose AV block resolved on the 21st day of the antiinflammatory treatment. Insertion of a pacemaker will also depend on institutional preference. Patients who are symptomatic should have a temporary pacemaker inserted and be considered for a permanent one.

In our case, syncope and AV block developed six days after the procedure. The block, which developed in the early period, and sinus rhythm resolved with high-dose steroid and acetylsalicylic acid. A careful clinical follow-up is planned in case late-period rhythm and conduction problems develop.

In conclusion, in the closure of VSD, especially perimembranous defects, with transcatheter method, AV block may develop in the early or late period given its adjacency to the conduction system. After the procedure, especially in the early period, the patients should be closely monitored clinically. The patient can be

hospitalized for one week after the operation for monitoring of rhythm. The heart blocks observed in the early period generally respond to the anti-inflammatory treatment. Use of high-dosage steroid and acetylsalicylic acid and placement of a temporary pacemaker might be convenient treatment approaches depending on the ventricular rate and the patient's symptoms. The major concern is the recurrence of complete AV block; therefore, very careful monitoring of rhythm is mandatory during the long-term follow-up.

REFERENCES

1. Lewis DA, Loffredo CA, Corre-Villasenor A, Wilson PD, Martin GR. Descriptive epidemiology of membranous and muscular ventricular septal defects in the Baltimore-Washington infant study. *Cardiol Young* 1996; 6: 281-290.
2. Butera G, Chessa M, Carminati M. Percutaneous closure of ventricular septal defects. *Cardiol Young* 2007; 17: 243-253.
3. Butera G, Chessa M, Carminati M. Percutaneous closure of ventricular septal defects. State of the art. *J Cardiovasc Med* 2007; 8: 39-45.
4. Çeliker A, Özkutlu S, Karagöz T, Erdoğan İ, Özer S, Aypar E. Device closure of congenital ventricular septal defects with Amplatzer devices: first experiences in Turkey. *Turk J Pediatr* 2008; 50: 106-113.
5. Ergene O, Eren NK, Akyıldız Zİ, Nazlı C. Percutaneous closure of ventricular septal defects in adult patients: our initial experience. *Arc Turk Soc Cardiol* 2009; 37: 312-316.
6. Fu YC, Bass J, Amin Z, et al. Transcatheter closure of perimembranous ventricular septal defects using the new Amplatzer membranous VSD occluder: result of the U.S. phase I trial. *J Am Coll Cardiol* 2006; 47: 319-325.
7. Hijazi ZM, Hakim F, Haweleh AA, et al. Catheter closure of perimembranous ventricular septal defects using the new Amplatzer membranous VSD occluder: initial clinical experience. *Cathet Cardiovasc Interven* 2002; 56: 508-515.
8. Butera G, Carminati M, Chessa M, et al. Transcatheter closure of perimembranous ventricular septal defects: early and long-term results. *J Am Coll Cardiol* 2007; 50: 1189-1195.
9. Zhou T, Shen X, Zhou S, et al. Atrioventricular block: a serious complication in and after transcatheter closure of perimembranous ventricular septal defects. *Clin Cardiol* 2008; 31: 368-371.
10. Walsh MA, Bialkowski J, Szkutnik M, Pawelec-Wojtalik M, Bobkowski W, Walsh KP. Atrioventricular block after transcatheter closure of perimembranous ventricular septal defects. *Heart* 2006; 92: 1295-1297.
11. Yip W CL, Zimmerman F, Hijazi ZM. Heart block and empirical therapy after transcatheter closure of perimembranous ventricular septal defect. *Cathet Cardiovasc Interven* 2005; 66: 436-441.